

**Presentation
Number:** 24

**Publishing
Title:** Midterm Outcomes After Pre-arteriotomy Guidewire Access (PAGA) with Antegrade Recanalization in Patients with Extensive Aortoiliofemoral Occlusive Disease without the use of a Re-entry Device

Author Block: Carlos F. Bechara, MD MS, George Pisimisis, MD, Neal R. Barshes, MD MPH, Panos Kougas, MD, Peter H. Lin, MD
Baylor College of Medicine, Houston, TX

INTRODUCTION: A pre-arteriotomy guidewire access (PAGA) was described to treat bulky iliofemoral occlusive disease. A wire is passed first from the groin into the aorta prior to the arteriotomy to increase technical success. Achieving retrograde intraluminal access in extensive aortoiliofemoral (AIFOD) occlusive disease can be a challenge. We modified the PAGA technique to successfully recanalize extensive aortoiliofemoral occlusion performed with adjunctive femoral artery reconstruction as an alternative to extra-anatomic bypass in high risk patients for aortobifemoral bypass (ABF).

METHODS: We approach these cases via a left brachial approach and groin cut down. Once brachial access is obtained, the patient is systematically heparinized. Then a 90-cm destination sheath is placed in the distal aorta. A stiff guidewire and a guide catheter are used to recanalize the chronic AIFOD. The wire is passed in an antegrade fashion across the AIFOD all the way towards the femoral head. A femoral arteriotomy is done to capture the wire thus establishing access from the groin into the patent aorta. External iliac artery and Femoral artery endarterectomy is performed around the wire. The wire is passed through the patch prior to completing the patch angioplasty. Once femoral revascularization is done, a sheath is placed over the wire, and retrograde iliac stenting is performed to the level above the patch to avoid crossing the inguinal ligament.

**Abstract
Body:**

RESULTS: This procedure has been performed in 18 patients (13 critical limb ischemia, 5 claudicants) with 94.4 % technical success without the use of a re-entry device. Fourteen (77.8%) patients required femoral endarterectomy with patch angioplasty, while 4 required interposition graft. Ten (55.5%) patients were done under spinal anesthesia. All patients had significant cardiopulmonary comorbidities and 5 had multiple abdominal surgeries. One (5.5%) patient had a superficial wound infection treated with oral antibiotics. One (5.5%) patient died within 30 days (massive MI), and one patient required an axillobifemoral bypass at 6 months for acute stent occlusion. The remaining 17 patients are symptom free with patent stents at a mean of 16.5 months (12-22 months).

CONCLUSION: Modified PAGA can be used to safely revascularize high-risk patients with extensive AIFOD with acceptable complication rate and patency. This procedure is currently offered to patients with aortoiliofemoral disease, not candidates for ABF, instead of an extra-anatomic bypass.

Presentation Number:25

Publishing Title: Robotic Vascular Surgery

Author Block: Petr Stadler, MD,PhD.

Na Homolce Hospital, Praha 5, Czech Republic.

OBJECTIVES: The feasibility of laparoscopic aortic surgery has been adequately demonstrated.

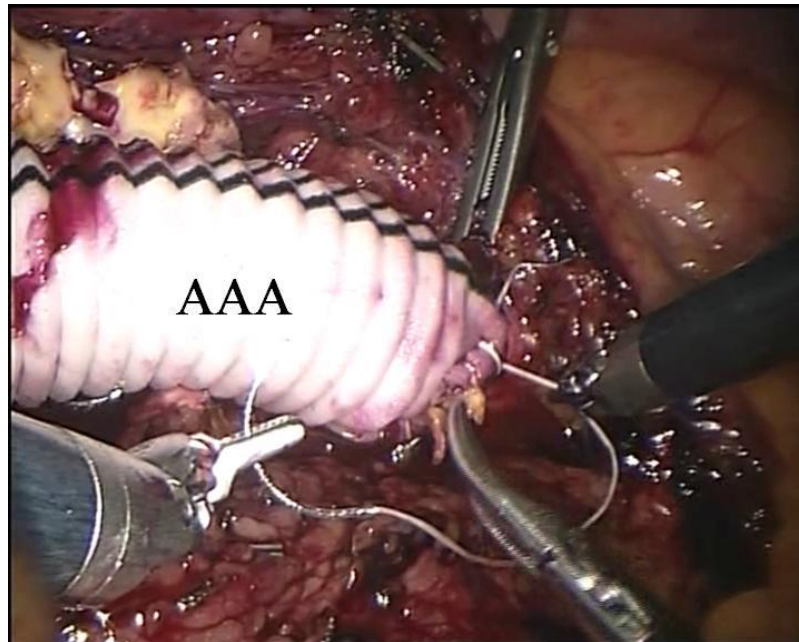
Our clinical experience with robot-assisted aortoiliac reconstruction for occlusive diseases, aneurysms, endoleak II treatment and hybrid procedures performed using the da Vinci system is herein described.

METHODS: Between November 2005 and August 2013, we performed 290 robot-assisted vascular procedures. 212 patients were prospectively evaluated for occlusive diseases, 57 patients for abdominal aortic aneurysm, four for a common iliac artery aneurysm, three for a splenic artery aneurysm, one for a internal mammary artery aneurysm five for hybrid procedures, and eight for endoleak II treatment post EVAR. The robotic system was applied to construct the vascular anastomosis, for the thromboendarterectomy, for the aorto-iliac reconstruction with a closure patch, for dissection of the splenic artery, and for the posterior peritoneal suture. A combination of conventional laparoscopic surgeries and robotic surgeries were initially included. A modified, fully-robotic approach without laparoscopic surgery was used in the last 120 cases in our series.

RESULTS: 279 cases (96%) were successfully completed robotically, one patient's surgery was discontinued during laparoscopy due to heavy aortic calcification. In tent patients (3,4%) conversion was necessary. The thirty-day mortality rate was 0,3%, and early non-lethal postoperative complications were observed in six patients (2%).

CONCLUSIONS: Our experience with robot-assisted laparoscopic surgery has demonstrated the feasibility of this technique for occlusive diseases, aneurysms, endoleak II treatment post EVAR and hybrid procedures. The da Vinci robotic system facilitated the creation of the aortic anastomosis, and shortened the aortic clamping time as compared to purely laparoscopic techniques.

Abstract Body:



Presentation Number: 26

Publishing Title: **Alternative access techniques with thoracic endovascular aortic repair: open iliac conduit vs. endoconduit technique**

Author Block: **Guido H. van Bogerijen, MD¹**, David M. Williams, MD², Jonathan L. Eliason, MD³, Narasimham L. Dasika, MD², G. Michael Deeb, MD⁴, Himanshu J. Patel, MD⁴

¹Departments of Vascular and Cardiac Surgery, University of Michigan Cardiovascular Center, Ann Arbor, MI, ²Department of Radiology, University of Michigan Cardiovascular Center, Ann Arbor, MI, ³Department of Vascular Surgery, University of Michigan Cardiovascular Center, Ann Arbor, MI, ⁴Department of Cardiac Surgery, University of Michigan Cardiovascular Center, Ann Arbor, MI

OBJECTIVES: Iliac artery endoconduits have emerged as important alternatives to retroperitoneal open iliac conduits to aid in transfemoral delivery for thoracic endovascular aortic repair (TEVAR). We present the first comparative analysis of these alternative approaches.

METHODS: All patients undergoing TEVAR (n=577, 1993-2013) with either retroperitoneal open iliac conduit (ROIC, n=23) or internal endoconduit (EC, n=15) were identified. The mean age of the cohort was 72.3 ± 11.6 years (81.6% female). A univariate analysis comparing the two groups is listed in Table 1. The primary outcome was the composite rate of late limb loss, claudication or repeat revascularization.

RESULTS: Device delivery was accomplished in 100% of cases. Early mortality was seen in 1 patient (2.6%) undergoing endoconduit. 2 year KM survival for the entire cohort was 76.3%, and did not differ between groups (ROIC 78.3% vs. endoconduit 73.3%, p=0.583). At a median follow-up of 10.3 months, the incidence of iliofemoral complications was 7.9%. Limb loss was seen in 1 patient after endoconduit. Repeat revascularization occurred in 1 patient after ROIC. Finally, claudication occurred in 1 patient after endoconduit. No variables were identified on univariate analysis as predictive of iliofemoral complications, likely due to the low event rate. Actuarial analysis showed that 12 month freedom from iliofemoral complications was 92.1%, and did not differ between device delivery strategies.

CONCLUSIONS: This early comparative evaluation of alternative access routes for TEVAR suggests that an endoconduit approach is safe, effective and associated with low rates of early mortality and late iliofemoral complications. The endoconduit may be considered an appropriate delivery route for transfemoral thoracic endovascular aortic repair.

Abstract Body:

Patient characteristics with univariate analysis			
Variable	Endoconduit (N = 15)	Open conduit (N = 23)	P value
Age (years)	72.2 ± 7.2	72.3 ± 7.3	0.98
Female sex	12 (80.0%)	19 (82.6%)	1.00
Peripheral vascular occlusive disease	5 (33.3%)	6 (27.3%)	0.73
Preoperative ipsilateral ankle-brachial index	0.93 ± 0.28	1.03 ± 0.09	0.22
Minimum iliofemoral size (mm)	4.62 ± 1.96	6.11 ± 1.25	0.03
Device delivery size (French)	22.46 ± 1.85	24.14 ± 1.03	0.01

Presentation Number: 27

Publishing Title: Lumivascular Approach To Crossing Chronic Total Occlusions Without Fluoroscopy

Author Block: Tom Davis, MD
St. John Hospital and Medical Center, St Clair Shores, MI

PURPOSE: To demonstrate a case series where the use of optical coherence tomography (OCT) greatly reduced or eliminated fluoroscopy during the crossing of peripheral arterial chronic total occlusions when using the Ocelot catheter (Avinger, Redwood City, CA).

MATERIALS AND METHODS: Fifteen patients were treated for peripheral arterial chronic total occlusions (CTO) between January 2013 and June 2013. Sixteen lesions were crossed using real-time OCT as the primary imaging modality in these cases. The mean patient age was 73 years (range, 50-91 years). Ten males and 5 females were treated. Radiographic values measured included diagnostic angiography, CTO crossing fluoroscopy, and therapeutic fluoroscopy times.

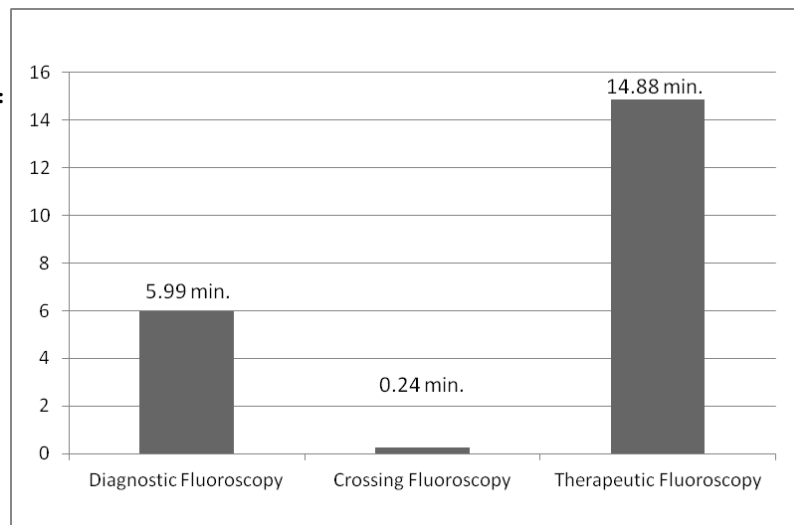
Table 1. Characteristics of Case Series Demographics, Lesions and Fluoroscopy Times

RESULTS: One hundred percent of CTOs in this series were crossed successfully via the true lumen without the use of assist or reentry devices. Mean CTO crossing fluoroscopy time was 0.24 ± 0.36 minutes (14.4 \pm 21.6 seconds) using the Ocelot (Figure). In comparison, mean diagnostic and therapeutic fluoroscopic times were 5.99 ± 3.07 minutes and 14.88 ± 6.36 minutes, respectively. Mean lesion length treated was 18.6 cm (18.63 ± 8.58 cm). 16/16 lesions were reduced from 100% stenosis to less than 10% stenosis. In 15/15 cases, the mean contrast volume administered across procedures was 176.66 ± 50.08 mL (median, 180 mL; range, 100-230 mL). There were no adverse events reported at 60 days.

Figure 1. Measured Fluoroscopy Times

CONCLUSION: Lumivascular techniques allow for safe, quick, and efficient crossing of peripheral arterial CTOs while eliminating or significantly reducing fluoroscopic exposure and contrast administration.

Abstract Body:



Presentation Number: 28

Publishing Title: Percutaneous and Surgical Femoral Arterial-Venous Fistula in an Ovine Model

Carlos E. Donayre, MD¹, George Kopchok, BS², Brad Kellerman¹, Gene Reu¹.

Author Block: ¹LA BioMed Research Institute at Harbor-UCLA, Torrance, CA, ²LA BioMed Research Institute at Harbor / UCLA, Torrance, CA

OBJECTIVE: Prospective comparison of a percutaneous versus an open femoral arteriovenous fistulas in an ovine model

METHODS: Six femoral AV fistulas were created utilizing standard side-to-side anastomoses with loupe magnification (Group A) in an ovine model. Six femoral percutaneous AV fistulas were also created in an ovine model utilizing high-definition ultrasound imaging to cannulate the femoral vein, and to direct a specially designed crossing wire from the femoral vein to the adjacent femoral artery. A catheter designed to bring the femoral artery and vein close together was then introduced and computer-control heat was applied to create a thermal resistance seal designed to hold the artery and vein together, with a concentric aperture between the artery and vein, creating an arterial-venous fistula (Group B).

RESULTS: Both groups were survived for 15 and 30 days with duplex ultrasound follow-up imaging of femoral artery and vein, dimension determination, assessment of vessel and fistula patency, proximal venous outflow, and histopathological evaluation of the excised specimens. See attached table. The variable data did not attain statistical significance.

Histopathologic data confirmed patency determined by ultrasound and exhibited comparable neointimal tissue response and maturation between both methods.

CONCLUSION: Creation of percutaneous arteriovenous fistulas was successful in a femoral ovine model and compared favorably with fistulas created utilizing open surgical techniques. In this model prone to intimal hyperplasia formation avoidance of suture and foreign body reaction and lack of disruption of the vascular bed at the anastomotic site may have implications with regards to patency and fistula maturation. Utilization in humans with end stage renal disease appears feasible.

Abstract Body:

Comparison pAV fistula vs Surgical AV fistula		
	Surgical Fem AV Fistula (n=6)	Percutaneous Fem AV Fistula (n=6)
Arterial diameter	4.0 mm	3.4 mm
Initial vein diameter	3.4 mm	3.3 mm
Vein diameter at explant	4.4 mm	4.6 mm
Initial fistula length	10.0 mm	4.7 mm
Fistula length at explant	6.3 mm	5.1 mm
Initial fistula flow	NA	769 ml/min
Fistula flow at explant	866 ml/min	505 ml/min
Patency	83%	100%

**Presentation
Number:** 29

**Publishing
Title:** A comparison of surgical approaches for cervical rib resection for neurogenic thoracic outlet syndrome

Author Block: Arjun Jayaraj, MD, Audra A. Duncan, MD, Manju Kalra, MD, Thomas C. Bower, MD, Peter Gloviczki, MD.
Mayo Clinic, Rochester, MN

**Abstract
Body:**

OBJECTIVE: The presence of a cervical rib in 1% of the general population can often be symptomatic, causing neurogenic thoracic outlet syndrome (nTOS). Surgical treatment has been most commonly described through a supraclavicular incision or a combination of supraclavicular (SC) and transaxillary (TA) dissections. In an effort to avoid a supraclavicular incision, particularly in young patients, completely transaxillary cervical rib resections were done and their outcomes evaluated.

METHODS: In a single center retrospective review, we analyzed peri-operative and outcome data on subjects undergoing cervical rib resection for nTOS between 1994 and 2013.

RESULTS: Of the 75 operations performed for nTOS, 40% (30 procedures in 29 patients) required resection of cervical ribs in 25 women (87%) and 4 men (13%). Mean age was 37 (13-68 range). The first and cervical ribs were removed in 24 cases, whereas only the cervical was resected in 6. Scalenetectomy was performed in all patients. 13 (43%) procedures were done with a supraclavicular only (SC) approach, 9 (30%) with a transaxillary only (TA) approach, and 8 (27%) with both incisions (TA+SC). The most common perioperative complication was pneumothorax occurring in 1 (8%) of SC, 4 (44%) of TA, and 1 (13%) of the TA+SC group. There were no instances of brachial plexus or other nerve injury. Incidence of persistent nTOS symptoms occurred in 3 (23%) of SC patients, 1 (13%) TA patient, and 2 (25%) TA + SC patients. (p=NS) Recurrence of symptoms was noted in one patient (8%) in the SC group at 1 year follow up. No patient required operative reintervention.

CONCLUSIONS: Resection of cervical ribs, often in addition to first ribs, in treatment of nTOS can be safely done through SC, TA or a combined approach. In young patients, a TA incision may be considered to avoid a neck incision, with similar outcomes to alternate approaches.

Presentation Number: 30

Publishing Title: **Robotic removal of a symptomatic inferior vena cava filter**

Mark E. O'Donnell, MMedSc MD FRCS, Scott M. Cheney, MD, Erik P. Castle, MD, Grant T. Fankhauser, MD, Richard J.

Author Block: Fowl, MD, William M. Stone, MD, Samuel R. Money, MD.
Mayo Clinic, Phoenix, AZ

OBJECTIVES: Percutaneous inferior vena cava (IVC) filter placement has successfully replaced ligation or interruption procedures as the optimal interventional modality for pulmonary embolism prophylaxis. However, IVC filter deployment is not without risk and may be associated with puncture site bleeding, higher venous thrombotic or occlusion rates as well as filter migration and perforation.

METHODS: We present the successful robotic removal of a symptomatic IVC filter.

RESULTS: A 23-year old female presented with deteriorating severe right lower back and right upper quadrant pain with associated left lower extremity discomfort. She had a previous history of left lower extremity DVT five years ago. She had been prescribed oral contraceptives for two months but was otherwise well with no other prothrombotic risk factors. Venous duplex imaging confirmed left iliac vein thrombosis. She proceeded to left common iliac vein stenting for presumed May-Thurner syndrome combined with retrievable IVC filter insertion. Warfarin therapy was continued for two months. She had two failed attempts to retrieve the IVC filter the following year due to filter had migration and perforation of struts through the IVC wall. Clinically, she had mild generalised abdominal tenderness and no evidence of any lower extremity arteriovenous pathology. CT venography identified three separate filter struts that had perforated the IVC adjacent to the duodenum and lumbar vertebrae wall. Due to severe ongoing pain, the patient was scheduled for robotic removal of her IVC filter. Patient positioning was completed using a modified 30° flank position with slight table flexion and reverse trendelenberg positioning. After creation of the pneumoperitoneum, a 12mm camera port was inserted followed by insertion of the remaining robotic ports under direct vision (5mm x 1,8mm x 3 and 12mm x 1). Key procedural steps included mobilization of the duodenum and right colon, IVC dissection using Split and Roll technique, vascular control of the IVC, creation of the cavotomy, mobilization and robotic fracture of the IVC filter struts, removal of the IVC filter followed by closure of the cavotomy. The patient made an uneventful recovery and was discharged well on post-operative day-two. She remains symptomatically well six-months later.

Abstract Body:

CONCLUSIONS: Following failed percutaneous retrieval, we suggest robotic removal of IVC foreign bodies as a safe and less morbid technique providing shorter recovery and improved patient quality of life.