

ePoster Abstracts

Presentation Number: P1

Publishing Title: Distal Digital Embolization from an Occluded Radiocephalic Arteriovenous Fistula: Case Report and Review of the Literature.

Author: Michael F. Amendola, MD¹, Marc Posner²

Block: ¹VA Medical Center/VCU Health System, Richmond, VA, ²VCU Health System, Richmond, VA

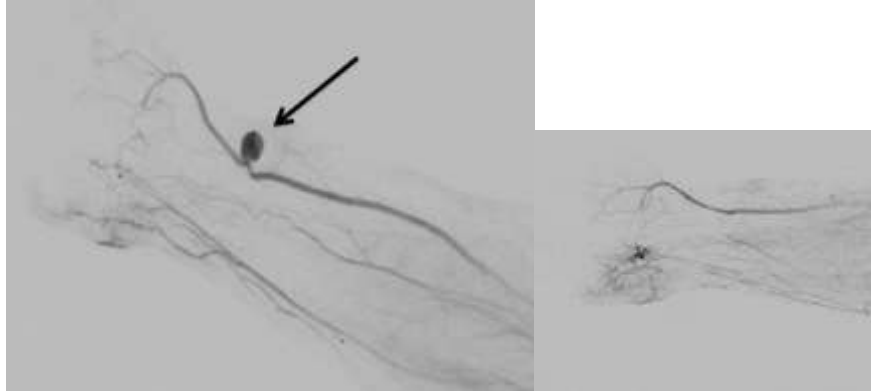
INTRODUCTION: Radiocephalic fistulae are the first line recommended arteriovenous access in patients with end stage renal disease. These fistulae have a well-established thrombosis rate.

METHODS: We report a case of a 45-year-old male who presented to our medical center with a four-week history of right digital blue discoloration. He was initially examined by his primary care physician and started on calcium channel blockers for Raynaud's Disease. He presented to our emergency department secondary to increasing pain in his digits. Vascular duplex demonstrated triphasic waveforms in his radial artery with associated aneurysm degeneration of the proximal aspects near the arterial anastomosis. His past medical history was significant for kidney transplant with current immunosuppression regiment of mycophenolate mofetil, tacrolimus, and prednisone. He was taken to the operating room and underwent an angiogram confirming distal embolization of the distal digital arteries (Figure 1). There was an aneurysmal degeneration of the proximal stump of the occluded radio-cephalic fistula. The aneurysm resected and the radial artery reconstructed in an end-to-end fashion (Figure 2). Eight milligrams of tissue plasmin activator was placed into the radial artery and injected toward the digits. At clinic follow-up he has decreased vasospasm symptoms in his hand with resolving pain.

RESULTS: Giant aneurysmal degeneration of brachio-cephalic fistulae in renal transplant patients on immunosuppression has been described in the literature. Corticosteroids have a known association with native artery aneurysmal formation; however, a proposed mechanism is purely speculative. Aneurysmal degeneration of thrombosed radiocephalic fistulae with distal embolization in kidney transplant patients has only been described in three cases in the literature with large ranging durations of immunosuppression (days to years).

Abstract Body:

CONCLUSIONS: Aneurysmal degeneration of occluded radio-cephalic fistulae is a rare complication of arteriovenous fistula access. Distal embolization is an even rarer presentation of occluded arteriovenous fistulae. This case study should serve as a warning to physicians following occluded arteriovenous fistulae in transplant patients on immunosuppression.



Presentation Number: P2

Publishing Title: HIV and Arterial Thromboembolism as Cause of Acute Limb Ischemia: 2 Case Reports

Author Block: **Simpledeep Banipal, MD**, Carl Valentin, MD, Daniel Katz, MD, Samantha Minc, MD
Mount Sinai Hospital, Chicago, IL

OBJECTIVES: Human immunodeficiency virus (HIV) infection has been linked to a hypercoagulable state. Despite this, there have been few case reports about arterial thromboembolism in HIV patients with no other predisposing factors. We present two case reports of young females with a history of HIV found to have arterial thromboembolism as the cause of acute limb ischemia.

METHODS: Two case reports and brief review of the literature.

RESULTS: Patient A is a 41-year-old female with a recent diagnosis of HIV presenting with acute onset right lower extremity pain for 2 weeks and CTA findings of thrombus in the popliteal artery, anterior tibial artery and tibial-peroneal trunk. The patient was treated with catheter directed thrombolysis for 3 days, resolving the thrombus in the popliteal artery. Patient B is a 39-year-old female with a longstanding history of HIV and a distant history of embolic stroke with left hemiparesis, presenting with a 3-day history of right lower extremity pain. The patient was found to have near occlusive thrombus in the aorta with a short segment of left common iliac artery thrombus and occlusion of the right iliac and common femoral artery. The patient had reconstitution of the right superficial and profunda femoral artery but went on to occlude distal to the popliteal artery (figure 1a). The patient was treated with bilateral iliofemoral and aortic thrombectomy (figure 1b). The cardiac echo failed to show a cardiac origin of embolism in either patient. The patients were treated with long-term anticoagulation with warfarin.

CONCLUSIONS: This case study documents the management of two young HIV positive females presenting with limb ischemia as the result of non-cardiac thromboembolic events. We used both operative and pharmacologic therapies to address this issue. HIV has been linked to hypercoagulable events, with venous thromboembolism (VTE) being studied more than arterial thromboembolism. It has also been noted that patients with HIV and VTE might not respond to anti-coagulation with warfarin or enoxaparin. More studies are needed to address arterial thromboembolism in HIV infected patients along with long-term anticoagulation treatment options.

Abstract Body:

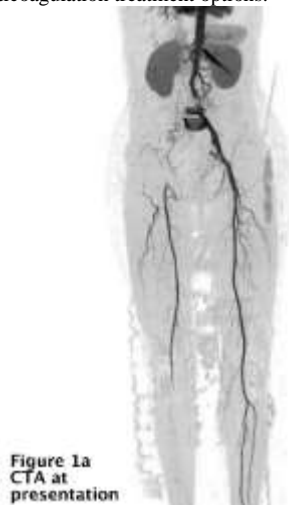

Figure 1a
CTA at
presentation

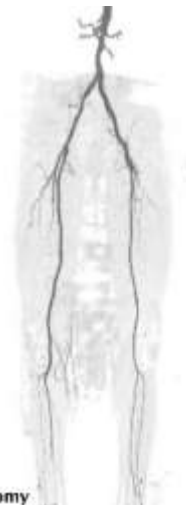


Figure 1b
CTA after
thrombectomy

Presentation Number: P3

Publishing Title: Axillobifemoral bypass in the 21st Century; Do Results Vary According to Operative Indication?

Author Block: Aurelia T. Calero, MD, Paul Armstrong, Martin Back, Dennis Bandyk, Brian Park, Brad Johnson, Neil Moudgill, Peter Nelson, Murray Shames, Karl A. Illig
University of South Florida, Tampa, FL

Abstract Body:

OBJECTIVES: Axillofemoral bypass is a well-established alternative in patients who are unable to undergo anatomic reconstruction. Two different indications for its use, however, exist: revascularization after treatment of infectious aortic pathology and revascularization for arterial occlusive disease. The goal of this study was to review and update our experience with this operation, specifically focusing on differences in outcome between patients operated upon for infectious versus occlusive problems.

METHODS: Retrospective analysis of patients undergoing axillo-femoral bypass from January 2000 to December 2012 at a single institution was performed. Patients with revision of an existing graft, temporary grafts during aneurysm repair, and insufficient information or follow up were excluded. Primary endpoints were primary patency, primary assisted patency, secondary patency, limb salvage, and survival, and patients were stratified according to whether the indication for operation was aortic infection (infectious) or aortoiliac occlusive disease (occlusive). Life table analysis with Cox hazard ratios were calculated between groups.

RESULTS: During this timeframe 112 patients underwent axillo-femoral bypass by 6 surgeons. 59 patients had occlusive versus 48 patients with infectious disease. There were 82 axillobifemoral, 14 axillo-unifemoral, 2 axillo-profunda femoris, and 1 axillo-superficial femoral artery bypass. Operative details were available on 101 patients, and reliable follow up existed on 69. Of the 101 patients analyzed, 30-day mortality was higher in infectious group (25% vs. 10%). Overall primary patency at 1, 3 and 5 years was 68%, 53% and 53%, while secondary patency at the same intervals was 83%, 73%, and 73%. Primary patency was numerically better in the infectious group (1 year: 81% vs. 65%; 5 year: 67% vs. 50%) although overall differences did not reach significance ($P < 0.2$). Survival was better in the occlusive group (5 years: 70% vs 36%; $P < .02$), but limb salvage was no different (5 years: 96% vs. 91%, P -value 0.19).

CONCLUSIONS: In our experience, axillobifemoral bypass in the 21st century is associated with approximately 50% 5-year primary patency and 75% secondary patency. Patency seems to be slightly better in patients operated upon for aortic infectious problems, while survival is better in those operated upon for occlusive disease, likely highlighting the severity of aortic infectious problems.

Presentation Number: P4

Publishing Title: Autogenous Femoral-Femoral Crossover Bypasses: Use in Cases of Infection or Hypercoagulability

Author Block: Hayley Chang, Benjamin B. Chang, MD, Philip S. Paty, MD, Sean P. Roddy, MD, Kathleen J. Ozsvath, MD, Chin-Chin Yeh, MD, John B. Taggart, MD, Yaron Sternbach, MD, Paul B. Kreienberg, MD, Manish Mehta, MD, MPH, R. Clement Darling, III, MD

Albany Medical College, Albany, NY

OBJECTIVES: Patients presenting with unilateral infected inflow prosthetic reconstruction present a difficult clinical dilemma. One option is an autogenous femoral-femoral crossover bypass. This retrospective study analyzes the indications and effectiveness of autogenous femoral-femoral crossover bypasses.

METHODS: From 2000 to 2014, 23 patients underwent autogenous femoral-femoral crossover bypasses. These were employed in two general circumstances; first, as a means of leg revascularization in cases where there was an infected prosthetic graft in the recipient groin, and secondly in patients with hypercoagulability in whom previous prosthetic crossover bypass had failed. Follow up involved serial examination and noninvasive studies at six-month intervals. Patients who underwent femoral-femoral bypasses with synthetic grafts were excluded from this study.

Abstract Body:

RESULTS: Over a 14 year period, 736 femoral-femoral crossover bypass was performed; 23 were autogenous. In 15 cases, this reconstruction was employed due to infection at the common femoral artery of the recipient limb. The infected previous reconstructions included aortobifemoral bypasses, axillofemoral bypass or iliofemoral bypass. In 8 cases, autogenous bypass was used in cases in which there was unilateral inflow occlusive disease in hypercoagulable patients who had already had failure of a prosthetic crossover bypass. Autogenous greater saphenous vein was employed as conduit in 19 cases. There were no cases of graft infection in the entire group. Graft failure occurred in the early postoperative period in one patient due to poor conduit (spliced arm and short saphenous vein). One failure occurred in a hypercoagulable patient due to thrombosis of the aorta and donor iliofemoral artery. Over a mean follow-up of 39.1 months, patients with this vascular repair had a mean patency of 33.9 months.

CONCLUSIONS: In selected cases, the use of an autogenous femoral-femoral crossover bypass can be a useful tool in the management of some difficult clinical cases involving groin sepsis or hypercoagulability. The relative resistance of autogenous bypass to infection allows it to be used in cases in which there may be a higher chance for graft contamination. In addition, autogenous bypass may be useful in patients with coagulation disorders and unilateral inflow disease who have had failure of previous prosthetic bypass.

**Presentation
Number:** P5

**Publishing
Title:** Consequences of Hypogastric Artery Embolization, Ligation or Coverage in Vascular, ObGyn , Oncology and Trauma Patients

Author Block: **Gautham Chitragari, MBBS**, Felix J. Schlosser, MD, Ph.D, Bauer E. Sumpio, MD, Ph.D
Yale University School of Medicine, New Haven, CT

**Abstract
Body:**

BACKGROUND: Ligation, coverage or embolization(LCE) of the hypogastric artery (HGA) may result in ischemic complications. The aim of this study was to compare the rate and the risk factors for the development of ischemic complications after LCE of HGA in ObGyn, Vascular, oncology (ONC) and trauma patients.

METHODS: Databases were searched for articles containing data of patients who underwent LCE of HGA. Based on the indication, details of the procedure and complications developed, data collected was categorized and evaluated for any significant difference in outcome using chi-square test.

RESULTS: 121 papers and a total of 335 patients (mean age - 49.2 years; median-44 years) were included in the study. 30.7%(103/335) were male, 69.3%(232/335) were female. Indication for LCE was ObGyn related in 51.0%(171/335), vascular in 26.0%(87/335), ONC in 18.0%(60/335) and trauma in 5.0%(17/335) of patients Overall ischemic complication rate was 23.0%(77/335), including buttock claudication(12.2%), buttock necrosis(5.4%), lower limb ischemia(3.6%), spinal cord ischemia(3.3%), erectile dysfunction(2.9%) and colon ischemia(2.7%). Complication rate was 8.6%(10/116) after ligation, 31.4%(65/207) after embolization (p=0.01) and 25.0%(3/12) after covering of HGA. 32.3%(30/93) patients with unilateral LCE (mostly embolizations) of HGA developed complications compared with 19.8% of patients with bilateral LCE (mostly ligations)(p=0.07). Complications were fewer in patients aged 44 years (35%; 57/160; p=0.001). LCE of the origin of HGA produced less complications, 19.4%(48/247), compared to LCE of distal branches 69.2%(p<0.001). The use of gelfoam (28.6%), coils (35.5%) or Amplatzer plugs (33.3%) produced similar rate of complications(p=NS). Patients with vascular (38.2%), ObGyn (7.6%), ONC (35.6%) or trauma (62.5%) indications had different complication rates. The difference in complication rate between vascular and ObGyn patients was statistically significant (p<0.001).

CONCLUSIONS: Ischemic complications after LCE of the HGA depends on the indications, age and type of intervention. In patients older than 44 years, LCE of HGA should be done with caution. Proximal embolization is preferred over distal embolization and ligation of proximal HGA is preferred over embolization.

**Presentation
Number:** P6

**Publishing
Title:** Occluded Superficial Femoral and Popliteal Artery Stents: Negative Impact on Bypass Target

**Author
Block:** Allan M. Conway, MBChB (Hons), MRCS (Eng), Khalil Qato, MD, Danielle Bottalico, Joanelle Lugo, MD, Gary Giangola, MD, Alfio Carroccio, MD.

Lenox Hill Heart & Vascular Institute of New York, New York, NY

OBJECTIVES: Treatment of peripheral vascular occlusive disease involving the superficial femoral (SFA) and popliteal (POP) arteries is often initially approached with an endovascular technique rather than with a lower extremity bypass (LEB). Stent failure is known to occur, yet how this affects the initially available bypass target remains unclear. The purpose of this study was to identify whether occluded stents influence previously available lower extremity bypass targets.

METHODS: We retrospectively investigated patients who had undergone stenting of an SFA or POP artery lesion from January 2009 to December 2013 to identify patients with occluded stents. Angiograms at the time of stent placement were analyzed to determine what would have been the optimal distal bypass site. Following occlusion of the stent, we assessed for patency of the previously available distal bypass site based on angiography or duplex ultrasonography. This population was also investigated for risk factors associated with loss of the bypass target.

**Abstract
Body:**

RESULTS: We identified occluded stents in 32 limbs in 30 patients. Primary patency at 1-year was 68.8%. Fourteen (47%) patients were male and mean age was 69.9 years (range, 53.3-86.4). Stenting was performed for claudication in 20 (62.5%), non-healing ulcer/gangrene in 10 (31.3%) and rest pain in two (6.3%) limbs. There were five limbs (15.6%) with TransAtlantic InterSociety (TASC) II A, 12 limbs (37.5%) with TASC B, nine limbs (28.1%) with TASC C and six limbs (18.8%) with TASC D lesions. Of the patients with occluded stents, 7 (21.9%) lost the bypass target. In one limb (3.1%) the target changed from above knee to below knee popliteal, in two limbs (6.3%) from above knee popliteal to tibial, and in four limbs (12.5%) from below knee popliteal to tibial artery. Eleven patients (34.4%) required LEB during follow up, nine of which were initially treated for claudication. Of the 28 variables investigated for an association with loss of bypass target we identified four that were significant.

CONCLUSIONS: SFA and POP artery stent occlusion can affect target vessels in patients who may require subsequent LEB. This should be considered when performing stenting, especially in those with claudication.

**Presentation
Number:** P7

**Publishing
Title:** Urinary Retention after Carotid Endarterectomy

Author Block: Samantha R. Cox, DO, Joseph McShannic, MD, Lee Ann Marshall, Rn, BSN, John Moawad, MD, Drazen Petrincec, MD, John Fink, MD.
Summa Health System, Akron, OH

OBJECTIVE: To define the incidence of post-operative urinary retention in males greater than 50 years of age following carotid endarterectomy (CEA) while undergoing general anesthesia.

METHODS: A pilot study was conducted to determine the true incidence of postoperative urinary retention among the male carotid endarterectomy population over the age of 50 undergoing general anesthesia. Exclusion criteria included females, males < 50 years of age, use of regional anesthesia, current prostate medication regimen, previous cystectomy, urinary conduit surgery or prostatectomy, and history of prostate cancer. After obtaining IRB approval, a pilot study was conducted. A questionnaire designed by the AUA (American Urologic Association) was used to determine the severity of preoperative urinary retention. This permitted patient stratification into mild, moderate, and severe risk. Post-operatively, an order was placed to catheterize those patients experiencing symptoms of urinary retention or the inability to void within eight hours of surgery. Laboratory values and total urine output were monitored post-operatively.

**Abstract
Body:**

RESULTS: Twenty-two percent of the cohort (n=41) had urinary retention post operatively requiring either clean intermittent catheterization, Foley placement, or discharge with a leg bag. Pre-operative risk stratification of urinary retention predicted the probability of retention within each category. The 41 patients included for analysis were identified as, no risk, 50% (n=20), mild risk, 13% (n=23), moderate risk, 27% (n=15), severe risk, 100% (n=1).

CONCLUSION: The incidence of postoperative urinary retention in males greater than 50 years of age following carotid endarterectomy while undergoing general anesthesia is very likely. This phenomenon has been described in the literature and has been associated with longer length of hospital stay and increased morbidity, therefore, we believe there is a need for further research. In future studies we would like to consider development of a pre-operative protocol for management of those patients at moderate or high risk for post-operative urinary retention after CEA.

**Presentation
Number:** P8

**Publishing
Title:** Multicenter experience of surgical explantation of carotid artery stents for recurrent stenosis

Author Block: **Randall DeMartino, MD¹**, Jesse Columbo², John McCallum³, Philip Goodney, MD², Thomas C. Bower, MD¹, Marc Schermerhorn, MD³, Richard J. Powell, MD²
¹Mayo Clinic, Rochester, MN, ²Dartmouth-Hitchcock Medical Center, Lebanon, NH, ³Beth Israel Deaconess Medical Center, Boston, MA

OBJECTIVES: Carotid artery stent (CAS) is subject to restenosis that may require explantation. The purpose of this study is to describe the indication, treatment and outcomes of patients undergoing CAS explantation.

METHODS: A retrospective review of all patients undergoing explantation of CAS placed at the carotid bifurcation for internal carotid artery occlusive disease at three academic medical centers (2003-2013). Indications for explantation, prior treatments, mode of treatment, and outcomes were reviewed.

RESULTS: Over a 10 year interval, 8 patients underwent CAS explantation (mean age 69 +/-9.9yrs, 63% male). Stent placement was for prior neck surgery (2) and high lesion (3). Only 2 patients underwent angioplasty (1) or restenting (1) prior to explantation. Four patients presented with minor stroke and five had >70% in-stent restenosis. Mode of repair was endarterectomy with patch angioplasty in five and bypass with vein in three patients. Repair extended to C2 in 5 and C1 in one patient. Shunts were used in half of the patients. There were no post-operative strokes or cranial nerve injury. Postoperative complications included blood pressure lability requiring treatment (3) and pneumonia (1). Median follow-up was 16 months (range 5-107). One patient had >80% restenosis after bypass (136 days post-op) treated with angioplasty. Two late disabling strokes occurred (14 and 19 months) after patch repair, one was a known ipsilateral event from the prior repair site.

CONCLUSIONS: CAS explant in an uncommonly required procedure involving CAS removal with patch angioplasty or bypass. Although small, our series demonstrates safety and feasibility in patients deemed to have been anatomic high risk. However, restenosis and late stroke remain concerns despite explantation making patient selection critical.

**Presentation
Number:** P9

**Publishing
Title:** Successful Endovascular Exclusion of Secondary Aortobronchial Fistulas Requires Long-term Surveillance

Author Block: Carlos E. Donayre, MD, Ankur Gupta, MD, Irwin Walot, MD, George E. Kopchok, BS, Rodney White, MD.
Harbor / UCLA Medical Center, Torrance, CA

OBJECTIVE: Evaluate the use of thoracic endovascular aortic repair (TEVAR) to exclude secondary aortobronchial fistulas to prevent fatal hemorrhage when submitted to a long-term follow-up.

METHODS: Retrospective review of patients with prior history of aortic repairs presenting with massive hemoptysis, and who underwent endovascular exclusion of their aortobronchial fistulas at a single institution. Demographics, clinical history, outcomes, need for re-intervention, and radiological follow-up were collected for each patient.

RESULTS: Six patients, 4 males, 2 females, with an initial average age of 47.2 years (range 32 - 60 years) presented with massive hemoptysis and a prior history of aortic repair: coarctation (n=3), aortic transection (n=2), and aberrant right subclavian artery aneurysm (n=1). Length of time from open repair to presentation averaged 18.7 years (range 3 - 31 years). Diagnosis and treatment was often delayed averaging 33.3 days (range 1.5 - 150 days) from onset of symptoms to endovascular exclusion.

**Abstract
Body:**

There were no operative mortalities, average length of hospital stay was 8.3 +/- 0.5 days. Bronchoscopic cultures yielded one MRSA positive culture, and antibiotic were administered for 4-6 weeks. Follow-up of 75.3 +/-9 months revealed two recurrent episode of hemoptysis at 6 and 9 years, which were treated with a second TEVAR, again with no mortalities or adverse events. **CONCLUSION:** In patients with massive hemoptysis and a prior open or endovascular thoracic aortic repair presence of an aortobronchial fistula must be suspected. As opposed to TEVAR for aorto-esophageal fistulas, TEVAR for secondary aortobronchial fistulas appears to offer long-term exclusion. Lifetime surveillance is still recommended as to achieve a durable exclusion.

Presentation Number: P10

Publishing Title: Management of Difficult Access During EVAR

Author Block: Yana Etkin, MD¹, Ksenia Orlova, MD, PhD¹, Paul J. Foley, III, MD¹, Grace J. Wang, MD¹, Edward Y. Woo, MD², Jeffrey P. Carpenter, MD³, Ronald M. Fairman, MD¹, Benjamin M. Jackson, MD¹.

¹Hospital of the University of Pennsylvania, Philadelphia, PA, ²MedStar Health, Washington DC, DC, ³Cooper University Hospital, Camden, NJ

OBJECTIVES: To describe a large single institutional experience in managing challenging access situations during EVAR.

METHODS: Data from all patients undergoing EVAR at a tertiary academic medical center between 2009 and 2013 were collected retrospectively, including demographics, size of iliac arteries, type of device used, approach to managing difficult access, and outcomes. The median follow-up was 38 months. Difficult access (DA) was defined as having diameter of iliac arteries smaller than 7cm bilaterally. Fenestrated and snorkel repairs were excluded.

RESULTS: Out of 400 EVARs performed during the study period, 191 (48%) were done in patients with DA. Of these, 42 patients (22%) underwent adjuncts prior to introduction of the main body device: including 15 dilators, 11 balloon angioplasties, 9 AUI devices, 3 SoloPath sheaths, 1 retroperitoneal cutdown and 3 iliac stents. In another 35 patients, iliac stents were used to correct stenoses or kinks in the limbs after EVAR devices were deployed. The average diameter of the iliac artery used to deliver main body component was 48mm in the group of patients requiring adjuncts and 54mm in the rest of the patients with small iliac arteries (p=.008). The average size of the main body device was 28mm. Two cases were aborted due to inability to deliver the device. Other complications included 7 (3.6%) iliac ruptures, 3(1.6%) limb ischemia, 5 (2.6%) need for early reoperation. Two patients (1%) had type I endoleaks at the conclusion their EVAR. During follow-up, 12 (6.3%) of patients required EVAR revisions. Seven patients (3.6%) had limb thrombosis which occurred only in patients who did not have adjective procedures during the initial EVAR. Limb thrombosis and rate of revisions in patients with DA were not significantly different from the rates observed in non-DA patients. Perioperative mortality after elective repairs was 1.6% in DA patients and 0% in non-DA patients (p=0.12).

Abstract Body:

CONCLUSIONS: EVAR can be successfully performed even in patients with bilateral small iliac arteries. Adjunctive procedures might increase the technical success rate of EVAR in these patients, and should definitely be considered in patients with iliac arteries less than 50mm in diameter. Next generation and “low-profile” devices might minimize the need for adjunctive procedures and facilitate EVAR in these patients.

Presentation Number: P11

Publishing Title: The Implications of Increased Age and Urgent Indications on Outcomes Following TEVAR

Author Block: **Amarilys Fernandez-Maldonado**, Rami O. Tadros, Peter L. Faries, Marielle Torres, Sharif H. Ellozy, Windsor Ting, Ageliki G. Vouyouka, Michael L. Marin.

Icahn School of Medicine at Mount Sinai, New York, NY

OBJECTIVE: Thoracic aortic pathologies, such as dissections, penetrating ulcers, aneurysms, and traumatic injuries, are potentially life threatening medical conditions that require close observation and many times interventions. The purpose of this study is to determine if having elective or urgent indications for thoracic endovascular aneurysm repair (TEVAR) affects procedural outcomes.

METHODS: A retrospective review of a maintained database was performed on all patients undergoing TEVAR at a tertiary hospital from 2001 to 2013. Patients were categorized as having either an elective or urgent TEVAR. Demographics, intraoperative parameters, follow-up data, complications, endoleak rates and types, reinterventions, and mortality rates were compared between the two groups.

RESULTS: A total of 106 patients were categorized as having either an elective (73 patients) or urgent (33 patients) TEVAR. The mean age was 73.4 ± 10.7 years in the elective group and 69.7 ± 14.9 years in the urgent group ($P=NS$). The majority of the patients were male, 67.1% in elective cases and 51.5% in the urgent cohort ($P=NS$). Ethnicities did not vary between groups, with the majority being Caucasian (58.9% in elective, 42.2% in urgent, $P=NS$). Mean follow-up time was 2.68 ± 3.0 years for the elective group and 2.10 ± 2.7 for the urgent group ($P=NS$). Complication rates (intraoperative, perioperative, and late onset) had a three-fold increase in the urgent group when compared to elective cases (36.4% vs. 11.0%, $P=0.001$). Length-of-stay (LOS) doubled in the urgent group when compared to the elective group (16.3 ± 13.4 days vs. 8.3 ± 20.9 days, $P=0.069$). There was no difference in 30-day aneurysm-related and 30-day all-cause mortality between the elective and the urgent groups ($P=NS$). Overall, the all-cause late mortality in this cohort is high, 41.1% in the elective group and 36.4% in the urgent group ($P=NS$). Patients ≥ 70 years-of-age had a two-fold increase in all-cause mortality when compared to patients under the age of 70 (53.7% vs. 20.5%, $P=0.001$).

CONCLUSIONS: Having an urgent indication for TEVAR triples the complication rate and doubles the LOS when compared to elective cases. All-cause mortality rates are two-fold higher in patients ≥ 70 years-of-age. These findings should be considered when planning TEVAR.

Abstract Body:

Mean follow-up time, complications, length of stay and mortality			
Parameter	Elective Group No. (%) (N=73)	Urgent Group No. (%) (N=33)	P value
Mean follow-up time \pm SD, years	2.68 ± 3.0	2.10 ± 2.7	NS
Any complication	8 (11.0)	12 (36.4)	0.001
Intraoperative complications	1 (1.4)	2 (6.1)	NS
Perioperative complications	5 (6.8)	6 (18.2)	0.067
Late onset complications	4 (5.5)	5 (15.2)	0.087
Length-of-stay \pm SD, days	8.3 ± 20.9 days	16.3 ± 13.4	0.069
30-day TAA-related mortality	1 (1.4)	1 (3.0)	NS
All-cause late mortality	30 (41.1)	12 (36.4)	NS

**Presentation
Number:** P12

**Publishing
Title:** Atypical Management of Infected Thoracoabdominal Graft and Aortobronchial Fistula

Author Block: **Patricia Giglio, BA**, Virendra I. Patel, MD MPH.
Massachusetts General Hospital, Boston, MA

OBJECTIVES: To present the case of a patient who underwent successful atypical management of a thoracoabdominal aortic graft infection and to suggest this alternative approach may be a viable treatment option in similar high risk patients.

METHODS: The aortic graft infection was successfully managed by thoracic endovascular stent graft repair (TEVAR) and visceral debranching with omental wrap followed by long term antibiotic treatment.

RESULTS: Our patient presented with an aortobronchial fistula and a thoracoabdominal graft infection caused by *Proteus mirabilis*. The patient underwent a temporary bridge procedure consisting of visceral debranching, infrarenal aortic reconstruction, and stent graft coverage of the pseudoaneurysm. After a period of recovery on long-term suppressive antibiotics, the infection resolved and the second stage procedure (graft excision and reconstruction using left atrial femoral bypass) was unnecessary. The patient remains asymptomatic and fully functional three years after the stage one procedure.

**Abstract
Body:**

CONCLUSIONS: The standard management for aortic graft infections is explantation of the graft, debridement of the infected area, in-situ reconstruction with an antibiotic-impregnated graft or extra-anatomic reconstruction, and vascularized omental or intercostal muscle wrap, followed by long term antibiotic suppression. However, this aggressive approach is not a viable treatment option in some high risk patients. The success of this case suggests that visceral debranching to enable a distal landing zone for TEVAR and chronic antibiotic suppression may be a new treatment option in similar high risk patients.

**Presentation
Number:** P13

**Publishing
Title:** **Operative Management of Ruptured Abdominal Aortic Aneurysms in the Elderly**

Author Block: Micah E. Girotti, MD, Anna Eliassen, MD, Katherine A. Gallagher, MD, John E. Rectenwald, MD, Jonathan L. Eliason, MD,
Dawn M. Coleman, MD.

University of Michigan, Ann Arbor, MI

OBJECTIVES: Although elective open and endovascular aortic aneurysm repair (EVAR) in the elderly is documented as safe, justification for interventions on ruptured aneurysms remains unclear given the increase in perioperative mortality in patients >80 years old. This study evaluates the safety and efficacy of open surgery and EVAR for ruptured abdominal aortic aneurysm (rAAA) in the elderly at an institutional and national level.

METHODS: A retrospective review of a single center experience with rAAA was performed. The patient population was stratified as elderly (age \geq 80) and non-elderly (NE); analysis was performed based on type of repair (open vs. EVAR). Primary outcomes included complications and 30-day mortality. Univariate regression was used to analyze the effect of independent variables on the primary outcomes. A Kaplan-Meier (KM) analysis for survival was performed. Additionally, national trends in post-operative complication and mortality were similarly assessed using 2008-2009 NSQIP data.

**Abstract
Body:**

RESULTS: 69 patients were managed between 2003 and 2013. Eighteen (26%) were elderly. The elderly and NE cohorts were similar in demographics, comorbidities, and aneurysm size. In the elderly cohort 8 patients underwent EVAR and 10 underwent open repair. 30-day mortality rates were 12.5% and 80% respectively (P=0.03). In the NE cohort 21 patients underwent EVAR and 30 patients underwent open repair. 30-day mortality rates were 19% and 30% respectively (P=0.52). Despite elderly patients being significantly more anemic, hypothermic and hypotensive, outcomes for the two groups were similar. Sub-set analysis of open repair and EVAR in the elderly revealed significantly lower rates of complications (100% v. 42.9%, P=0.02) and a trend toward shorter length of stay in the EVAR cohort. Final sub-set analysis of all EVAR patients revealed no differences in outcomes between elderly and NE patients. Analysis of NSQIP data revealed similar results with no statistically significant difference in major morbidity or mortality following EVAR. National sampled 30-day mortality rates were 34.2% for octogenarians undergoing EVAR for rAAA in comparison to 25.8% for younger patients (P=0.17).

CONCLUSIONS: National and institutional data suggest that elderly patients fare as well as younger patients following EVAR for rAAA. Given high rates of morbidity and mortality, decisions to offer open repair to elderly patients should be made thoughtfully and with clearly defined expectations.

**Presentation
Number:** P14

**Publishing
Title:** Carotid Artery Stenting and Aortic Arch Vessel Cannulation Using The Magellan Endovascular Robotic System: An Animal Series

Author Block: **Sung Wan Ham, MD¹**, Joie C. Dunn, MD², Michael Sigman, MD¹, Christopher Yi, MD², Erlinda Kirkman, DVM, SRS², Fred A. Weaver, MD, MMM¹.

¹University of Southern California, Division of Vascular Surgery, Los angeles, CA, ²University of Southern California, Department of Surgery, Los Angeles, CA

OBJECTIVE: An endovascular robotic system capable of remote catheter and sheath steerability has been used successfully in a variety of vascular beds in highly select centers in the United States. Its potential safety profile has been demonstrated with regard to aortic arch cannulation using the robotic system, however data is limited to pulsatile phantom models of the aortic arch.

Therefore, we report our experience with the Magellan robotic system applied to carotid interventions and arch vessel cannulation in the porcine model with a focus on technical feasibility and histologic vessel trauma analysis.

METHODS: A consecutive series of short-term, non-survival experiments were performed in the porcine model. The Magellan robotic system was used to navigate and selectively cannulate the carotid and left subclavian arteries and deliver therapy using conventional endovascular devices. Aortic arch aortograms and standard selective cerebral angiograms were performed pre- and post-procedure. Immediate post mortem necropsy included gross tissue evaluation for intimal injury to the ostia of the great vessels and carotid bifurcation. Subsequent histopathologic analysis was performed to grade the severity of vessel wall injury using a published grading system already established in the porcine model.

**Abstract
Body:**

RESULTS: Seventeen carotid and 6 left subclavian artery stenting procedures were performed in 10 animals by a single operator. All carotid stents were delivered in conjunction with commercially available embolic protection devices followed by routine post balloon dilation. There was 100% technical success with arch vessel cannulation and delivery of carotid and subclavian artery stents with no incidence of sheath instability. One animal died unexpectedly from a cardiac event before intervention was performed. On gross necropsy, there was no evidence of intimal injury to the ostia of the arch vessels or carotid bifurcation. Histopathologic analysis revealed no major injury to the internal elastic lamina, tunica media, or external elastic lamina in all cannulated ostia.

CONCLUSIONS: Carotid stenting and aortic arch cannulation is technically feasible using a robotically steerable catheter/sheath system and can be performed with minimal to no vessel trauma in the animal model. The Magellan Endovascular robotic system provides a stable sheath platform in the delivery of standard endovascular devices and its use may be potentially safer particularly in distant and tortuous vascular beds.

Presentation Number: P15

Publishing Title: Carotid Endarterectomy in Asymptomatic Patients: Using the ACS-NSQIP Database to Shed Light on Gender Differences

Jamal J. Hoballah¹ MD, MBA; Anthony G. Haddad², MD; Elie P. Ramly^{1,3}, MD; Hani Tamim, PhD²

Author Block: ¹Department of Surgery, American University of Beirut Medical Center, Lebanon, ²Department of Internal Medicine, American University of Beirut Medical Center, Lebanon, ³Department of Surgery, Massachusetts General Hospital, Boston, MA

OBJECTIVE: Gender differences in outcomes after CEA in asymptomatic patients remain unresolved. The objective of this study was to compare 30-day postoperative stroke, myocardial infarction and mortality outcomes between asymptomatic male and female patients undergoing carotid endarterectomy (CEA) from a prospective validated outcomes registry.

METHODS: Data from The American College of Surgeons' National Surgical Quality Improvement Program (ACS-NSQIP) database was obtained for the time period of 2008 to 2012 using CPT codes for CEA. Patients with a preoperative history of neurologic symptoms were excluded, keeping only asymptomatic patients for analysis. Demographics, preoperative comorbidities and postoperative mortality and morbidity data were retrieved. Multivariate logistic regression models were used to assess the independent effect of gender on stroke, mortality and myocardial infarction (MI), while controlling for the pertinent preoperative and intraoperative risk factors.

Abstract Body:

RESULTS: Data for 29,818 patients who underwent CEA was obtained, 17,640 (59.1%) of whom were males and 12,178 (40.9%) were females. 199 (1.1%) males and 171 (1.4%) females suffered a postoperative stroke ($p=0.034$). There were no significant differences in baseline characteristics, both groups were comparable except for females who were more likely to have a higher mean Body Mass Index (BMI) (28.57 ± 6.54 as compared to 28.40 ± 5.44 in males; $p < 0.001$). On multivariate analysis, female gender independently predicted higher postoperative rates of stroke [OR = 1.30 (95% CI: 1.06-1.60), $p = 0.013$] and MI [OR = 1.29 (CI: 1.01-1.64); $p = 0.038$]. There was no statistically significant increase in postoperative mortality [OR = 1.29 (CI: 0.93-1.77), $p = 0.124$].

CONCLUSION: In a retrospective cohort of asymptomatic ACS-NSQIP patients undergoing carotid endarterectomy, female gender was found to be an independent predictor of 30-day postoperative stroke and myocardial infarction, but was not associated with an increased risk of death.

Presentation Number: P16

Publishing Title: Fenestrated and Branched Repair of Thoracoabdominal Aneurysms in Octogenarians

Author Block: **Vikalp Jain, MD**, Raghuv eer Vallabhaneni, MD, Corey A. Kalbaugh, MSMA, William A. Marston, MD, Mark A. Farber, MD. University of North Carolina, Chapel Hill, NC

INTRODUCTION: Thoracoabdominal aortic aneurysms present a specific and complex challenge for vascular surgeons. As patients are living longer and there is a decrease in operative morbidity and mortality associated with endovascular management of these aneurysms, the number of patients who have access to branched and fenestrated repair has expanded. We evaluated our experience in the endovascular treatment of thoracoabdominal aneurysms in octogenarians when compared to those patient less than 80 years old.

METHODS: Prospectively collected data was analyzed in a retrospective manner. Inclusion criteria were any patient that underwent a fenestrated or branched endograft with either a commercially available device, or was enrolled in a corporate or physician-sponsored investigational device exemption trial. Data regarding patient's age, preoperative comorbidities, complications including arrhythmia, endoleak, kidney injury, paraplegia, myocardial infarction (MI), stroke, respiratory failure, and mortality were collected and analyzed using the chi square test and the fisher exact test.

RESULTS: Eighty-nine endovascular fenestrated/branched aortic aneurysm repairs were performed. Thirty-six patients had implantation of a sponsored investigational device. Mean follow-up was 7.8 months (Range: 2 days-3.2 years). Twenty-two (25%) of these patients were 80 years of age or older at the time of their repair with a mean age of 82.2 (Range: 80-87). Non-octogenarians had a mean age of 69.7 (Range: 55-79). Octogenarians were noted to have more pre-existing comorbidities including a higher rate of arrhythmia (p=0.02), hypertension (p=0.04), and prior stroke (p=0.02). Forty-one percent of octogenarians compared to 28% of non-octogenarians (p=0.25, NS) developed any complication after surgery as listed in the Table below. There were more frequent arrhythmias in the octogenarians but these did not lead to long-term morbidity in any cases. There were no other statistical differences in short-term and overall complication rate or hospital mortality between the two groups.

CONCLUSIONS: FEVAR for thoracoabdominal aneurysms is safe in octogenarians based upon early follow-up. This cohort, although with significantly higher comorbidities, has a similar complication profile when compared to those patients less than 80 years of age. Studies looking at multi-institutional data and long-term outcomes are needed to further evaluate the effectiveness of FEVAR in this population.

Abstract Body:

Early Complications			
	Age <80 (n=67)	Age > 80 (n=22)	p-value
Any complication, n, %	18 (28)	9 (41)	0.25
MI, n, %	0	0	1
Stroke/TIA	0	0	1
Paraplegia	0	0	1
Renal Failure	0	1 (5)	0.25
Arrhythmia	1 (2)	3 (14)	0.05
Bleeding	13 (20)	4 (18)	0.85
Vascular Complication	3 (5)	2 (9)	0.27
Hospital Mortality	1 (1)	1 (5)	0.38

**Presentation
Number:** P17

**Publishing
Title:** Transfemoral Denver Shunt in Patients with Chylous Ascites and Superior Vena Cava Obstruction

Author Block: Arjun Jayaraj, MBBS, Peter Gloviczki, MD, Linda G. Canton, RN
Mayo Clinic, Rochester, MN

**Abstract
Body:**

OBJECTIVES: Nonmalignant chylous ascites refractory to medical therapy can be effectively treated with peritoneo-venous Denver-shunt (CareFusion Corp, San Diego, CA), placed into the superior vena cava via the internal jugular vein. We present a case where shunt placement through an alternate access via the femoral vein was successfully utilized.

METHODS: A 63 year old male with yellow nail syndrome had medically refractory chylous ascites. He had a thrombosed superior vena cava (SVC) due to multiple previous Denver shunts. The inferior vena cava (IVC) via the right great saphenous and femoral veins was used to provide an alternate channel for drainage of his chylous ascites.

RESULTS: Under general anesthesia a small right groin crease cutdown was performed to expose the sapheno-femoral junction. The previously placed thrombosed Denver shunt was removed through a small incision at the neck and paracentesis of 4.6 liters of chylous ascites was then performed. A new 11.5Fr double valve Denver shunt was prepared and the peritoneal component inserted using the prior tract. Subsequently, the venous component of the shunt was tunneled subcutaneously, anterior to the anterior superior iliac spine, and brought into the right groin wound. The venous component was inserted into the common femoral vein via the saphenous vein and then advanced into the IVC. Location was confirmed using fluoroscopy. Anticoagulation was restarted in the postoperative period with Eliquis (Bristol-Myers Squibb Company, NYC, New York) and he was discharged on postoperative day one. On follow-up he was symptomatically better with a well functioning shunt.

CONCLUSIONS: Use of IVC via the saphenofemoral access for drainage of ascites is a safe and feasible option in patients undergoing Denver shunt placement with obstructive pathology of the SVC. Further follow up is necessary to confirm long term outcomes and assess the risk of IVC and shunt thrombosis.

**Presentation
Number:** P18

**Publishing
Title:** Post-market Study of the Zenith® Spiral-Z® AAA Iliac Leg Graft

Thomas F. Lindsay, MD¹, **Omid Jazaeri, MD**², Thomas Forbes, MD¹, Feiyi Jia, PhD³.

Author Block: ¹University of Toronto, Toronto, ON, Canada, ²University of Colorado School of Medicine, Aurora, CO, ³Med Institute, West Lafayette, IN

OBJECTIVES: Although uncommon, graft limb occlusion continues to plague endovascular abdominal aortic aneurysm repair. Endograft kinking, tortuous anatomy and occlusive burden have been identified as risk factors. This study reports outcomes from a prospective multicenter registry describing physician experience with the Zenith® Spiral-Z® AAA Iliac Leg Graft.

METHODS: The Spiral-Z® Registry is a prospective, non-randomized registry that is designed to collect up to 600 consecutive patients at up to 30 sites in North America. Clinical outcomes were assessed at two time intervals, short-term (1-6 months based on the site's standard of care) and longer-term (12 months). Main study outcomes include limb occlusion, secondary intervention, endoleak, component separation, and stent fracture related to the Spiral-Z® graft.

RESULTS: Between March 2012 and August 2014, the registry prospectively collected procedural results on 389 patients (mean age 74±8.6 years, range 48-93 years; 87% male), with Spiral-Z® grafts implanted in 752 limbs. Aneurysms were aortic in 286 (74%) and aortoiliac in 103 patients (26%). Moderate to severe occlusive disease, calcification, and vessel tortuosity were present in 13%, 22%, and 33% of iliac arteries, respectively.

**Abstract
Body:**

Follow-up data were available for 250 patients in the short-term and for 72 patients in the longer-term. Unilateral limb occlusion was observed in 2 patients (occurring on days 0 and 1 post-procedure); in 1 patient, pre-procedure severe iliac tortuosity and difficulty deploying the main body were noted. Both patients underwent secondary interventions (thrombectomy in one and fem-fem bypass in one). Also, 4 patients underwent secondary interventions in 4 additional limbs for kink, partial thrombosis and/or compression of iliac leg component, and 1 patient received placement of bilateral leg extensions to extend the original leg components which were considered too short. No Spiral-Z®-related endoleak, migration, component separation, or stent fractures have been reported. Twelve deaths were reported; none were related to limb occlusion.

CONCLUSIONS: The Spiral-Z® leg graft is associated with excellent early patency rates. While data collection is ongoing, preliminary registry results support the performance of the Spiral-Z® leg graft in real-world practice, with a low limb occlusion rate and no migration, component separation, and stent fractures within 12 months.

Presentation Number: P19

Publishing Title: Validation of Geometric Solid Models for Planning Endovascular Repair of Complex Aortic Aneurysms

Author Block:

Omid Jazaeri, MD¹, Rajan Gupta, MD², Jennifer L. Wagner, AAS, RT, BS³, Khurram Rasheed, MD⁴, Michael Richards, PhD⁴, Robin Shandas, PhD³, Ankur Chandra, MD⁴

¹University of Colorado School of Medicine, Department of Surgery, Aurora, CO, ²University of Colorado School of Medicine, Department of Radiology, Aurora, CO, ³University of Colorado School of Engineering, Department of Bioengineering, Aurora, CO, ⁴University of Rochester School of Medicine, Department of Surgery, Rochester, NY

OBJECTIVES: Human anatomy is often difficult to appreciate with 2-dimensional imaging. Preservation of spatial relationships is crucial to the success of endovascular aneurysmal repair. To gain an appreciation for complex aortic anatomy, optimize graft placement, and assist with surgical planning, 3-dimensional solid models should prove valuable tools for increasing efficacy and efficiency of vascular treatment plans as well as for promoting a personalized approach to treatment. However, there are currently no standards or validation techniques to evaluate 3D reconstruction algorithms and in silico modeling methods. Original algorithms were developed to generate solid models in a time and cost effective manner. These processes were tested in 5 individuals previously treated for complex aortic anatomy using fenestrated devices.

METHODS: Computed tomography scans of 5 patients previously treated with fenestrated endografts were retrospectively modeled by both University of Colorado Department of Bioengineering and University of Rochester Center for Medical Technology and Innovation. Standard measurements for device planning, as directed per manufacturers IFU, were compared to 3-D measurements based on 2 different methods of generating 3-dimensional solid models. Differences in measurements and the resulting graft configurations were examined.

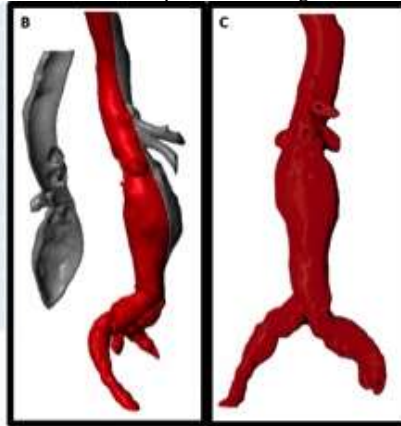
RESULTS: Measurements obtained from computer models and 3-D physical models are congruent with conventional measurements for all 5 patients. Differences observed (0-5mm) are due to different methods of measurement (along surface versus centerline) and inter-observer error. These differences did not translate into different endograft configurations when compared to patients treated. Figure 1 shows data from a representative patient.

CONCLUSIONS: Sizing measurements taken from solid models consistently correlate with standard sizing measurements supporting further investigation into use of 3-D models as important tools to improve accuracy in endograft customization for AAA repair. Understanding of measurement differences could be used to advance planning practices for sizing standard devices, investigational devices and physician modified endografts, as directed by an institutional IDE. Future work will include quantification of different error sources and comparison of measurement procedures using in silico and in vitro

Abstract Body:

A Comparison of Measurements				
Measurement	Conventional Method	URMC Computer Model	UCD Computer Model	UCD Physical Model
Bottom of Celiac to Middle of SMA (mm)	12	12	12	11
Bottom of Celiac to Middle of L. Renal (mm)	16	16	15	16
Bottom of Celiac to Middle of R. Renal (mm)	20	21	21	22
Bottom of Celiac to Bottom of R. Renal (mm)	31	32	32	33
Clock Face Location Celiac Artery	12:00	12:15	12:00	12:00
Clock Face Location SMA	12:00	12:00	12:00	12:00
Clock Face Location L. Renal	9:30	9:30	9:30	9:30
Clock Face Location R. Renal	3:00	3:00	3:00	3:00

Figure 1: Comparison of measurement techniques. **A** Table comparing measurements; **B** UCD computer model; **C** UCD physical model (ABS printed on Stratasys FDM machine)



models.

Presentation Number: P20

Publishing Title: Coil Embolization offers a simplified technique for treatment of venous perforator incompetence.

Author Block: **Charles S. Joels, MD**, Chris J. Lesar, MD, L. Richard Sprouse, MD, Mark W. Fugate, MD, Sachin V. Phade, MD.
UT Chattanooga, Chattanooga, TN

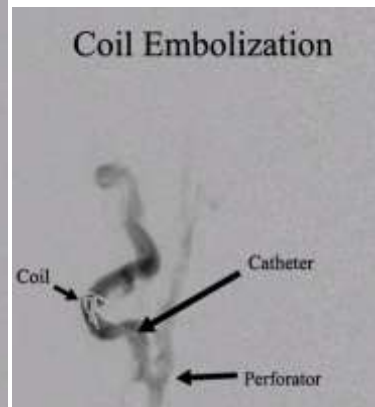
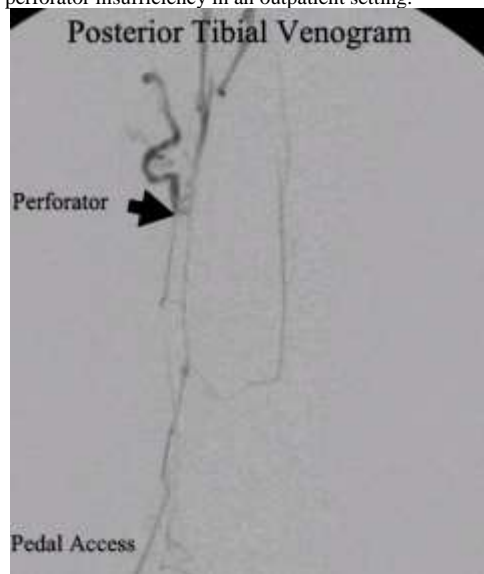
OBJECTIVES: Perforator incompetence is a common, but difficult to treat, aspect of CVI. The currently described therapies are cumbersome, often costly, and require specialized equipment which can limit the treatment venue. This study presents a novel, simplified technique that overcomes these obstacles.

METHODS: In this study incompetent venous perforators were treated in seven patients (eight legs) using venography and coil embolization. All patients were symptomatic (edema, ulceration, recurrent cellulitis). In all but one patient the diagnosis was made with preoperative duplex. Demographic and clinical data were reviewed retrospectively.

RESULTS: Venograms were performed after accessing the appropriate tibial vein in the lower leg and pushable coils deployed within the incompetent perforator using fluoroscopic guidance. All patients were treated on an outpatient basis, all but one in an office setting. Procedure success was 80% with two legs requiring multiple interventions. Symptom resolution by treated leg was 75%. One leg had persistent ulceration, another persistent edema. There were no DVT's or other significant complications.

CONCLUSIONS: Coil embolization offers an effective, low cost, less cumbersome, minimally invasive technique to treat perforator insufficiency in an outpatient setting.

Abstract Body:



**Presentation
Number:** P21

**Publishing
Title:** SMV Interposition Graft for Iatrogenic Injury During Right Hemicolectomy

**Author
Block:** Farah Karipineni, MD, MPH, Nyali Taylor, MD, Rashad Choudry, MD, FACS, Amit Joshi, MD, FACS.
Albert Einstein Medical Center, Philadelphia, PA

OBJECTIVE: Superior mesenteric vein (SMV) injury after abdominal surgery or major trauma is an uncommon complication associated with high mortality. Management is highly varied and most studies are confined to the trauma population rather than elective colorectal cases. This case report seeks to address the operative management of SMV injury during an elective right hemicolectomy.

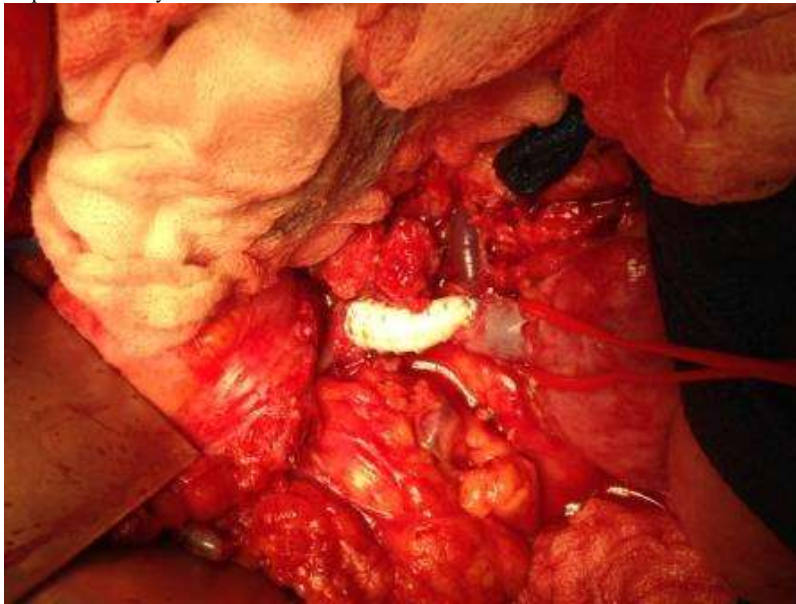
METHODS: A comprehensive chart review of the case was performed. Additionally, a literature search was performed on PubMed to identify all case reports, case series and studies addressing management of SMV injury, including both iatrogenic and traumatic events.

RESULTS: We report the case of a 73 year old female with biopsy-proven colonic adenocarcinoma who underwent laparoscopic hand-assisted right hemicolectomy complicated by SMV injury. The injury was managed with heparinization, temporary abdominal closure, SMV interposition graft with polytetrafluoroethylene graft (PTFE), and several trips to the operating room to re-assess bowel perfusion. No ischemic bowel was encountered, the patient was never hemodynamically unstable, and she was discharged on warfarin on hospital day 8 in good condition.

CONCLUSION: Options for management of SMV injury at the time of surgery are primary venorrhaphy, end-to-end anastomosis, interposition graft or bypass with PTFE or vein, and ligation. In the trauma literature, repair and ligation are associated with similar mortality rates, making ligation an acceptable approach in the setting of hemodynamic instability and potential polytrauma.

However, in patients undergoing elective surgery, revascularization should be attempted in the otherwise stable patient, and a high suspicion for delayed ischemic bowel should be maintained.

**Abstract
Body:**



Presentation Number: P22

Publishing Title: **Safety and Efficacy of Total Percutaneous Access for Fenestrated Endovascular Aortic Aneurysm Repair (pFEVAR)**

Author Block: **Martyn Knowles, MD,** David E. Timaran, Andrew W. Unzeitig, Iden D. Andacheh, M. Shadman Baig, R. James Valentine, Carlos H. Timaran.

University of Texas Southwestern, Dallas, TX

OBJECTIVES: Percutaneous femoral vascular access has become a common means of vascular access for aortic endovascular procedures, with a local complication rate in contemporary data of 9%. Recently, fenestrated endovascular aortic aneurysm repair (FEVAR) has emerged as a new technique for the repair of short-neck and juxtarenal aneurysms. The investigation of the use of percutaneous access in FEVAR has not been investigated to date.

METHODS: Since FDA approval, 57 patients (51 Zenith fenestrated [Zfen], 6 p-branch) underwent FEVAR at a single institution. Percutaneous access was performed using a “preclose” technique using the Proglide device (Abbott Vascular, Redwood City, Calif.). The total number of access sites was 124 (110 percutaneous, 4 open, and 10 brachial). The median femoral access size was 20F (IQR: 18-20) for percutaneous and 20F (IQR: 18.5-21.5) for open access. The most common configuration was a Zfen with a scallop for the SMA (n=31), Zfen with fenestration for the SMA (n=20) and p-branch (n=6). Median operative time was 210(IQR:174-277.5) minutes. Ten patients had a history of previous aortic surgery, and 8 had a history of previous groin surgery. There were 5 conduits performed at surgeon’s discretion: 4 endoconduits and 1 open retroperitoneal.

Abstract Body:

RESULTS: The percutaneous access success rate was 95.4%. There were 8 groin access site complications: 3 open (3/4;75%) and 5 percutaneous (5/110;4.5%)(P=.0009). The 3 open complications were a wound infection of a retroperitoneal conduit incision requiring percutaneous drainage and a bilateral groin infection with lymph leak. The 5 percutaneous complications were 2 tears with the device and hemorrhage, a backwall injury with flap, and an embolization requiring thrombectomy and fasciotomy. Previous aortic or groin surgery was not found to increase the risk of access site complications. The median operative time in the complication group was 308(IQR:210-395) minutes compared to 210(IQR:166-250) minutes in those without complication (P=.004). Use of an endoconduit for percutaneous access was associated with an increased complication rate (4/10 vs 0/100 access sites;p<.0001). Neither previous groin or aortic surgery influenced the complication rate.

CONCLUSIONS: Despite the increased operative time and complexity, percutaneous femoral access appears to be a safe alternative to open access in FEVAR patients. Cases with higher complexity, as manifested by the need for endoconduits and longer operative time, appear to have a higher percutaneous complication rate.

Presentation Number: P23

Publishing Title: Metastatic Para-Aortic Mass Resection Following Aortic Endograft Placement Resembling an Embryonal Carcinoma of the Testes

Author Block: Marc Leduc, MD, Ralph P. Ierardi, MD
Christiana Care Health Systems, Newark, DE

OBJECTIVES: A metastatic tumor of the retroperitoneum involving the region of the abdominal aorta is an uncommon entity in the vascular community. Recurrence rates of metastatic tumors decreases with time and only a few cases are documented of recurrence 10 years after initial presentation has been reported. The purpose of this case report is to describe the successful treatment of a retro-peritoneal tumor by aortic stent graft then subsequent resection in close proximity to the abdominal aorta. The placement of an abdominal endograft for resection of a tumor is rarely described in current literature.

METHODS: A 44-year-old Caucasian male with abdominal pain was admitted with an incidental finding of a 5x3 cm left para-aortic mass, left of the renal artery extending to the aortic bifurcation. The patient has a history of metastatic testicular cancer of the lung status-post left-sided orchiectomy treated with chemotherapy and resection of right pulmonary lesion approximately 15 years prior. The Alpha-fetoprotein serum was measured at 676.0. A CT-guided biopsy was performed, the pathology revealed positive cells for pankeratin and cytokeratin 7 along with a focal positivity for AFP, compatible with metastatic disease.

Abstract Body: Surgery was performed by lining of the aorta with a Gore-Tex excluder stent graft then subsequent laparotomy and resection of the tumor. Pathology showed the tumor demonstrated a poorly differentiated malignant neoplasm with features consistent of metastatic embryonal carcinoma. The patient completed two-cycles of adjuvant VIP chemotherapy.

RESULTS: Two months post-operatively, Duplex ultrasound demonstrated normal position of aortic endograft, no evidence of aneurysmal disease or perigraft flow. AFPs started normalizing which appear to be a biochemically responding status post resection. Two months post-operatively, the Alpha-fetoprotein serum was measured at 38.1, 6 months at 5.6.

CONCLUSIONS: Traditionally, metastatic tumors have been treated with systemic therapy. However, studies show long term survival after first line chemotherapy is contingent upon resection of Germ Cell tumors. Metastatic tumors with involvement of the abdominal aorta make resection difficult. Theoretically, the use of an aortic endograft may protect the resected sections, provide avoidance of future pseudoaneurysmal disease, and decrease surgical morbidity by potential avoidance of an aortic cross-clamp along with the associated fluid shifts and visceral ischemia. Long-term evaluation regarding the integrity of the endograft with neoadjuvant therapy and potential tumor recurrence should be addressed.

Presentation Number: P24

Publishing

Title: **Analysis of Emergency Vascular Surgery Consults Within a Tertiary Healthcare System**

Author Block: **Charles C. Leithead, MD**, Thomas C. Matthews, MD, Zdenek Novak, MD, Benjamin J. Pearce, MD, Mark A. Patterson, MD, Marc A. Passman, MD, William D. Jordan, Jr., MD

University of Alabama, Birmingham, AL

OBJECTIVES: Patients with vascular disease often have multisystem atherosclerosis and multiple comorbidities requiring comprehensive interdisciplinary specialty care. Consultation is a critical component of a tertiary Vascular Surgery practice, but analysis of this service is under

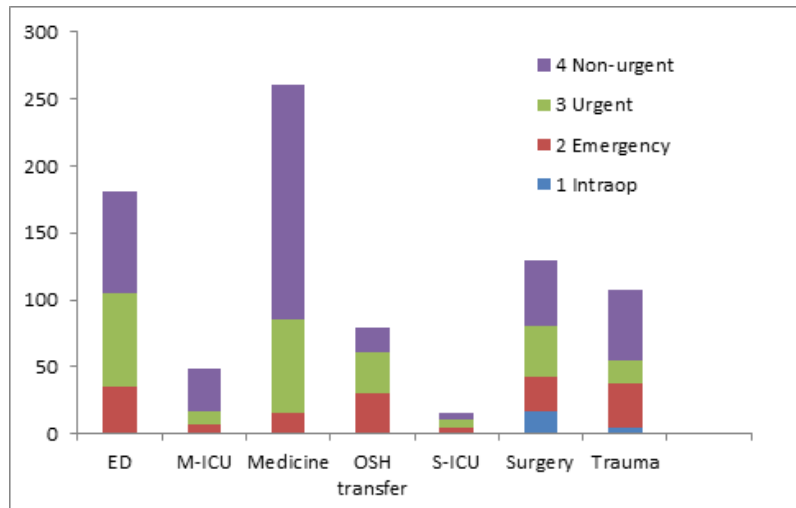
reported in literature. After hour (AH) inpatient consultations and interhospital transfers are associated with urgent patient care.

METHODS: A retrospective analysis of Vascular Surgery consultations was carried out from January 1, 2013 to December 31, 2013. Consultations included inpatient services, the Emergency Department (ED), Surgical and Medical Intensive Care Unit (ICU) and interhospital transfers. Data analysis included number of consults, time of consultation (during hours [DH] = 0700-1859 and AH= 1900-0659), referring service, nature, and outcome of consultation. Consultations were then classified as urgent if vascular surgical intervention (VSI) was required as an intraoperative consultation, within 24 hours, or during the same hospitalization. Patients without a same hospital VSI were classified as non-urgent.

RESULTS: Over a 1 year period, 823 independent consult requests on 749 patients were analyzed. It was found that 57.8% of AH consults resulted in urgent patient care ($p=0.03$). 66.7% of Medical ICU, 70.3% of Medicine, 58.1% of Trauma Surgery and 40% of ED AH consultations were non-urgent; 73% of Surgery and 79.2% of interhospital AH consults required urgent VSI. Extremity ischemia, aortic pathology and iatrogenic consults accounted for 44.8%, 20.4% and 11.1% of AH consults, with 57.9%, 56.4% and 70% requiring urgent VSI, respectively.

CONCLUSIONS: After hour consultations are not always associated with an urgent vascular surgical intervention. Non-urgent AH consultations are requested more frequently from some services and may present an opportunity for education that could improve efficiency of the vascular workforce.

Abstract Body:



Presentation Number: P25

Publishing Title: Five-Year Results from the Endurant Post-Approval Study of the Endovascular Treatment of Abdominal Aortic Aneurysms in the United States

Author Block: **John C. McCallum, MD**, Dominique B. Buck, MD, Jeremy D. Darling, BA, Peter A. Soden, MD, Sara L. Zettervall, MD, Marc L. Schermerhorn, MD.

Beth Israel Deaconess Medical Center, Boston, MA

OBJECTIVE: The Endurant Stent Graft System (Medtronic Cardiovascular, Santa Rosa, CA) is approved for the treatment of abdominal aortic aneurysms (AAA) by the FDA. Here, we report the results of the US investigational device exception (IDE) and post-approval study (PAS) cohorts of the Endurant Stent Graft Natural Selection Global Postmarket Registry (ENGAGE) with follow-up to 5 years.

METHODS: From 2008 to 2012, all patients with AAA treated under IDE or PAS with Endurant devices in the US (IDE, 31 sites; PAS, 24 sites) were included in the study. Patients receiving aorto-uni-iliac configurations were excluded. All-cause mortality, aneurysm-related mortality, freedom from rupture, and freedom from reintervention were analyzed via Kaplan-Meier survival analysis and are reported at 3- and 5 years.

Abstract

Body: **RESULTS:** A total of 328 patients (150 IDE, 178 PAS) were identified. Median follow-up was 2 years (SD 1.5 years) and 68 patients were followed the full 5 years. Overall survival at 3 and 5 years was 87.2% and 79.9%, respectively. Freedom from aneurysm-related mortality at 3 and 5 years was 99.4% and 98.5%, freedom from rupture was 99.7% and 98.8%, and freedom from secondary intervention was 90.2% and 85.2%, respectively. There were no conversions to open surgery during the study period. 7 (2.2%) stent graft occlusions occurred within 90 days, and 1 occurred at 4 years follow-up.

CONCLUSIONS: This is the first report of 5-year results for AAA treated with Endurant in the US. Rates of freedom from rupture, secondary intervention and aneurysm-related mortality compare favorably to long-term results for similar devices. 5-year follow-up for the full ENGAGE worldwide registry is expected in 2018.

**Presentation
Number:** P26

**Publishing
Title:** Endostaples for Distal Fixation in a Thoracic Endovascular Aortic Aneurysm Repair (TEVAR)

Author Block: **RATNA C. MEDICHERLA, MD**, Evan Lipsitz, MD.
Montefiore Medical Center, Bronx, NY

OBJECTIVES: We report a case of 77-year-old woman with an asymptomatic enlarging distal thoracic aortic aneurysm (TAA) treated with endovascular repair using endostaples.

METHODS: The patient was a former smoker with a history of hypertension, chronic kidney disease, asthma, and hypothyroidism. Physical examination was significant for a pulsatile mass in the mid abdomen. She was followed with serial computed tomographic angiography (CTA) for five years. The TAA measured 3.8cm in 2009 enlarging to 5.5cm in 2013. CTA revealed a short distal neck of approximately 5mm proximal to the celiac axis. Therefore, the decision was made to use endostaples for distal fixation.

RESULTS: After informed consent, the patient was taken to the operating room. A 7-French sheath was inserted via a right femoral exposure. Left common femoral artery was accessed percutaneously. An aortogram confirmed a short distal neck. The celiac artery was selected with a guidewire, and access was maintained in the hepatic artery with a glide catheter. A COOK Zenith TX2® 28mm x 80mm Endo Graft (Cook Medical, Bloomington, Ind) was deployed. Four Aptus Heli-FX Thoracic EndoAnchors (Aptus Endosystems Inc, Sunnyvale, CA) were placed at 2, 4, 8, 10 o'clock. A completion angiogram showed no endoleak and good filling of the celiac artery. The patient tolerated the procedure well without any complications. She was discharged the next day, and remains well at two month follow-up. Two month follow up CTA confirmed good placement of graft with no endoleak and aneurysm completely excluded.

**Abstract
Body:**

CONCLUSIONS: There are multiple options for obtaining distal fixation during TEVAR. These include coverage of the celiac axis, barbs/hooks on the graft, distal graft visceral uncovered bare metal stents, fenestrated/scalloped stent grafts, branched endografts, parallel stenting (chimney, snorkel, or periscope), and endoanchors/endostaples/endoscrows. This case is an example of a distal TAA with difficult anatomy due to a short distal neck treated with endovascular repair using endostaples to ensure distal fixation and reduce the risk of migration. Endostaples can serve as a safe and viable alternative that is minimally invasive for handling short landing zones. Early results with endostaples are promising, but further studies are warranted to evaluate long-term safety and durability. The ANCHOR registry is designed to evaluate patients from multiple sites treated with the Aptus Heli-FX EndoAnchor System and is currently enrolling.

Presentation Number: P27

Publishing Title: Management of Spontaneously Ruptured Splenic Artery Aneurysm in Pregnancy with Endovascular Stent-Graft: A Case Report

Author Block: Issa Mirmehdi, MD, Michael Fabian, MD
Halifax Health, Daytona Beach, FL

OBJECTIVES: Rupture of splenic artery aneurysm (SAA) is a rare condition that mostly occurs during pregnancy and carries a high maternal and fetal mortality. Initial hemorrhage into the lesser sac sometimes provides a very short window of opportunity for the diagnosis and treatment. Urgent or emergent surgical management is usually warranted. An endovascular approach was employed in the case presented here.

METHODS: A 24 year-old female in her 20th week of gestation presented with epigastric abdominal pain and hemorrhagic shock related to spontaneous rupture of a large SAA in the mid portion of the splenic artery. She was emergently taken to the

Abstract Body: endovascular suite and the ruptured aneurysm was successfully excluded from circulation with the use of a balloon-expandable stent-graft.

RESULTS: The patient regained hemodynamic stability following the procedure and was discharged home after 10 days of hospitalization. The fetus, unfortunately, did not survive. At one-year follow up, the patient remained asymptomatic.

CONCLUSIONS: Endovascular placement of a stent-graft is a less invasive alternative to open surgical repair in hemodynamically unstable patients with ruptured SAA. This technique also allows the maintenance of native blood flow through the splenic artery, which is preferred over endovascular embolization.

**Presentation
Number:** P28

**Publishing
Title:** Predictors of Neurological Deficits Following

Title: Endovascular Repair in Dissection versus Non-Dissection Aortic Pathology

Author Block: Albeir Mousa, MD¹, Mike Broce¹, Patrick Stone, MD¹, Zackary AbuRahma, DO¹, Michael Yacoub, MD¹, Gilbert R. Upchurch, Jr., MD², Ali F. AbuRahma, MD¹

¹RC Byrd Health Sciences Center, West Virginia University, Charleston, WV, ²University of Virginia, Charlottesville, VA

OBJECTIVES: The most dreaded outcomes after thoracic endovascular aortic repair (TEVAR) is neurological deficits (ND). The objective of this study is to report predictors of ND after TEVAR in dissection versus non-dissection aortic pathology.

METHODS: Multi-center, retrospective review of a prospectively maintained patient registry. The current data set was from the Virginias Regional group of the Society for Vascular Surgery® Patient Safety Organization (SVS PSO). All patients who underwent TEVAR were included. Basic demographic parameters, etiology, comorbidities, and TEVAR procedural details were all considered as potential confounding variables, which were included in logistic regression modeling to predict outcomes. The primary end point of ND is defined as any of the following; TIA, stroke, and paraplegia.

RESULTS: We analyzed 222 TEVAR procedures from the patient registry performed in 2012-2013. The majority of the patients were male (59.9%) with average (mean + SD) age 65.4 + 15.1 and BMI 27.9 + 5.7. The majority was non-dissection (66.2%) versus dissection aortic repairs (33.8%). Co-morbidities included chronic hypertension (82.9%), CAD (21.6%), CHF (9.0%), diabetes (16.7%), and prior or current tobacco use (79.3%). Forty-five patients (20.3%) had history of aneurysm and 53 (23.9%) had prior aortic surgery. We found no difference in ND rates for dissection (13.3%) versus non-dissection aortic pathology (10.9%) interventions (p=0.660). Following multivariate logistic regression, we found an increase in BMI is associated with decrease likelihood of ND odds ratio ((OR): 0.91, Confidence Interval (CI): 0.93-0.99; p=0.028). In addition, patients receiving TEVAR for emergency or aortic rupture were nearly 3 times as likely to experience ND (OR: 2.92, CI: 1.02-8.35; p=0.046). Neither previous aortic interventions nor length of stent graft were predictors for outcome (p=0.23, p=0.41) respectively. Other predictors such as covering left subclavian, celiac or occluded one or both hypogastric arteries were not also significant (p=0.498, p=0.499, p=0.203), respectively. However, these findings could be Type II error due to the small number of cases with covering and/or revascularization and corresponding ND outcomes.

CONCLUSIONS: ND is not uncommon after TEVAR emergent repair in Dissection aortic disease. Following TEVAR, the main predictors of ND were increase in BMI and emergent and/or aortic rupture conditions.

**Abstract
Body:**

Presentation Number: P29

Publishing Title: Surgical Management of a Mycotic Juxtarenal Aneurysm associated with Tuberculosis

Author: Gregory K. Nissen, MD, Ralph P. Ierardi, MD.

Block: Christiana Care Health Systems, Newark, DE

OBJECTIVES: Mycotic aneurysms resulting from *Mycobacterium tuberculosis* (TB) is a known but rare entity representing 0.85-2% of all abdominal aortic aneurysms. High mortality rate is associated with TB aortic aneurysms because rapid growth is common and classic presentation of aortic rupture if undiagnosed. A combination of surgical intervention and prolonged medical therapy is warranted for disease-free long term survival. The following report describes the successful surgical management and treatment of an aneurysm of the suprarenal aorta secondary to tuberculosis.

METHODS: An 81-year-old male, recently diagnosed with reactivation of military TB, presented with lower back pain associated with malaise and 30 pound weight loss. A CT scan of abdomen demonstrated a significant enlargement of an abdominal aneurysm found 3 months prior from 4.6-cm to 6.8-cm, with extension across the renal vessels.

A retroperitoneal approach was utilized for resection of aneurysm. After proximal and distal control was achieved, longitudinal arteriotomy was made posterior to the left renal artery extending through the infected inflammatory region. An extensive debridement of infected tissue was performed, followed by placement of a rifampin-bonded 18-mm Dacron graft that had been soaking in 50milligram rifampin solution over a 30-minute time interval. (Image)

RESULTS: Cultures were positive for *Mycobacterium tuberculosis*. Antituberculosis drug therapy was maintained for 12 months. Screening for associated pulmonary TB remained negative. One-year post-operatively, CT scan was normal and the patient remained well, asymptomatic, and inflammatory markers were normal.

Surgical approaches can include extra-anatomic bypass which long term offers lower patency and in situ reconstruction which does not carry increased risk of graft infection and allows assess to difficult diseased wall.

Follow-up data regarding an endovascular approach is limited and causes concern for the inability to effectively remove infected and necrotic tissue.

CONCLUSIONS: Medical and surgical treatment is required for treatment of tuberculosis mycotic aneurysms. Forty-one cases were reviewed and mortality was 100% (n=17) for patients not receiving both. This case reinforces the aggressive nature of tuberculosis mycotic aneurysms and certainly lends credence to an aggressive surgical approach employing the use of in situ reconstruction with antibiotic impregnated rifampin-bonded grafts for complex juxta and suprarenal aortic

Abstract Body:

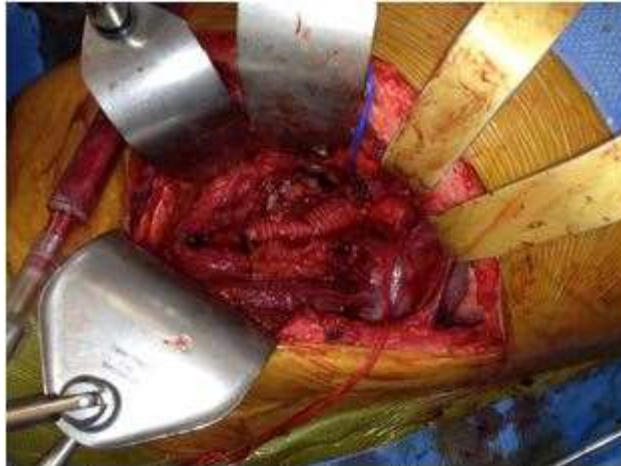

Image 1: In situ reconstruction of juxtarenal aorta with rifampin-bonded Dacron graft.

aneurysms.

Presentation Number: P30

Publishing Title: Transatlantic consensus of vascular surgery consent

Mark E. O'Donnell, MD FRCS¹, Cristine Velazco, MD², Ryan Day, MD², Damian McGrogan, MB MRCS¹, William M. Stone, MD², Richard J. Fowl, MD², Bernard Lee, FRCS¹, Michael G. Wyatt, MD FRCS³, Carolyn Pence-Smith, BA², Samuel R. Money,

Author Block: MBA MD²

¹Royal Victoria Hospital, Belfast, United Kingdom, ²Mayo Clinic, Phoenix, AZ, ³Freeman Hospital, Newcastle upon Tyne, United Kingdom.

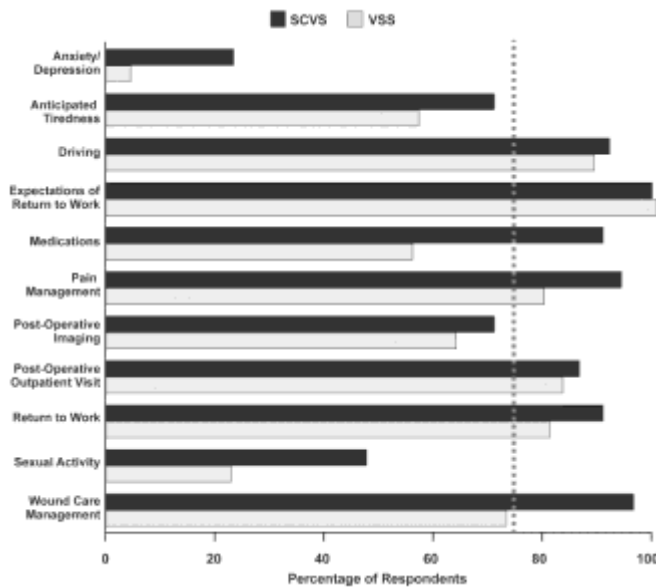
OBJECTIVES: Currently, there are no explicit guidelines for informed consent for vascular surgical interventions. The objective of this study was to compare current peer-practice and collate transatlantic consensus relating to vascular surgery patient consent.

METHODS: A prospective anonymous online survey was administered to members of the Society for Clinical Vascular Surgery (SCVS) and the Vascular Surgical Society of Great Britain and Ireland (VSS). Each member evaluated general and procedural specific complications for both arterial and venous interventions which should be discussed with patients during the informed consent process. Greater than 75% reporting for a specific complication was deemed the threshold for consensus opinion.

RESULTS: Overall response rate was 24.8%. The majority of respondents were attending surgeons (81.5% SCVS vs. 85.2% VSS). Both societies considered senior trainees competent to obtain consent. The majority of patients were consented primarily by the attending (67.6% SCVS vs. 90.6% VSS, $p < 0.01$) on a pre-printed consent form (95.1% SCVS vs. 98.7% VSS). Consent was obtained on the day of surgery in the office (35.4%-SCVS) or the day before surgery in the hospital ward (35.1%-VSS) with the provision of additional written documentation (59.2% SCVS vs. 85.4% VSS, $p < 0.01$). Both societies concurred with documentation of general arterial and venous complications including bleeding, cardiac, cerebrovascular, respiratory, thromboembolic and wound infection as well as more specific complications pertaining to aortic aneurysm, carotid endarterectomy, lower limb bypass, amputation and venous surgeries. Figure 1 delineates post-operative advice to patients provided by SCVS and VSS respondents with inclusion of a 75% consensus limit. Although the VSS reported a significantly higher consent training rate (14.1% SCVS vs. 40.8% VSS, $p < 0.01$), both societies stated this mainly involved ad-hoc informal training.

CONCLUSIONS: Whilst completion logistics of vascular consent vary, both SCVS and VSS members concur on the majority of complications necessary for inclusion in informed vascular consent. However, a formal consent training process for junior surgeons is warranted.

Abstract Body:



**Presentation
Number:** P31

**Publishing
Title:** Endarterectomy for Symptomatic Carotid Web: A Case Report

Author **John Phair, MD**, Eric Trestman, MD, Evan C. Lipsitz, MD.

Block: Albert Einstein College of Medicine at Montefiore, New York, NY

OBJECTIVES: To report a symptomatic carotid web, a rare entity histologically related to fibromuscular dysplasia, successfully treated with carotid endarterectomy.

METHODS: An extensive literature search was performed using the MEDLINE and Pubmed databases with few results in regards to symptomatic carotid web. The few reports in existing literature describe anomalous malformation of the internal carotid typically found incidentally. Even fewer cases in publication detail symptomatic carotid web lesions. No publications describe a common carotid web. The following search terms were used: carotid web, symptomatic carotid stenosis, fibromuscular dysplasia, endarterectomy and stroke. .

RESULTS: Case report: We report a case of a right common carotid web extending into the internal carotid artery creating an area of flow disruption, resultant in acute embolus formation and stroke. The diagnosis was evident with computed tomographic angiography results. This patient's condition was successfully managed with traditional carotid endarterectomy of the diseased segment.

CONCLUSIONS: This case represents the rare entity of a symptomatic carotid web. Arterial webs are an unusual arrangement of fibromuscular intraluminal in-growth. The creation of a steep intraluminal shelf within the neurovascular vessels creates a flow disturbance resulting in the risk of symptomatic or potentially catastrophic disease.

Abstract

Body:

Presentation Number: P32

Publishing Title: Superior Mesenteric Artery Aneurysm Rupture: A Case Report

Author Block: **Shahin Pourrabbani, MD**, Mauricio Szuchmacher, MD, K.v. Krishnasastry, MD, FACS.
North Shore LIJ Medical Center, Manhasset, NY

OBJECTIVES: Although visceral artery aneurysms are mainly asymptomatic, more than 90% of SMA aneurysms are symptomatic⁷. Intermittent abdominal pain is the most common clinical presentation. Other symptoms include a palpable mass, fever, nausea, gastrointestinal bleeding, jaundice, anemia, and shock⁸. The main risk associated with SMAAs is rupture, which has a high rate of mortality. We present a case of a male with abdominal pain who was found to have a superior mesenteric artery aneurysm rupture.

METHODS: An 88 year old male presented to the emergency department with syncope and abdominal pain that started several hours prior to admission to a local hospital. An abdominopelvic CT scan revealed a ruptured superior mesenteric artery aneurysm with hemoperitoneum. The patient was transferred to our facility hemodynamically unstable.

Abstract

Body: **RESULTS:** A cutdown of the left common femoral artery was performed. Using endovascular access techniques, an aortogram was performed and an occlusive balloon was then inflated to obtain proximal control. Subsequent laparotomy revealed two liters of blood. A large hematoma was noted in the mesentery. Upon evacuation, a 0.5-cm hole was noted. The aneurysm was resected and primary anastomosis performed. The patient tolerated the procedure well without complication.

CONCLUSION: A superior mesenteric artery aneurysm is a rare, but serious life-threatening condition. All patients should be highly considered for interventional procedures. Treatment options are available for patients at good operative risk (open surgical repair), and patients with comorbidities (endovascular techniques). In the case of our patient, emergent surgical intervention involving both endovascular occlusive balloon and laparotomy was required for repair of a SMAA rupture.

Presentation Number: P33

Publishing Title: Procedural Predictors and Related Resource Drain of Lower Extremity Ischemia after Aortic Surgery

Author Block: **Khurram Rasheed, MD**, James C. Iannuzzi, MD, MPH, Adam Doyle, Ankur Chandra, MD, John RT Monson, MB BCh, MD, Fergal J. Fleming, MB BCh, MD, Michael C. Stoner, MD
University of Rochester Medical Center, Rochester, NY

BACKGROUND: There is limited data regarding lower extremity ischemia following aortic aneurysm repair. This study's aim was to assess for factors associated with lower extremity ischemia following open abdominal aortic aneurysm repair (AAA) and Endovascular abdominal aortic aneurysm repair (EVAR).

METHODS: The National Surgical Quality Improvement Program database and vascular procedure Specific data was abstracted for the years 2011-2012. Cases entered for AAA and EVAR were evaluated for factors associated with lower extremity ischemia (LEI). Student's T-Test, Chi-squared, and Fisher's exact test were used to assess for statistical significance with two-tailed alpha set to $p < 0.05$. Binary logistic regression was then performed in EVAR retaining factors meeting $p < 0.05$.

RESULTS: Overall, 3734 cases were analyzed comprising 949 AAA, and 2785 EVAR cases. LEI incidence was 1.8% (n=68), 2.4% (n=23) in AAA versus 1.6% (n=45) after EVAR, $p=0.108$. Patient factors associated with LEI included: male sex ($p=0.047$), preoperative sepsis ($p=0.003$), preoperative transfusion ($p=0.018$), and operative time ($p < 0.001$). Procedural factors associated with LEI following EVAR included renal stenting ($p=0.021$), Iliac branched device usage ($p=0.003$) conduit access vessel repair ($p=0.039$), prior abdominal surgery ($p=0.036$), presenting with ruptured aneurysm ($p=0.002$), and thrombotic surgical indication ($p < 0.001$). On multivariable analysis the following factors remained significant: iliac-branched device (OR 2.94, CI 1.49-5.77, $p=0.002$), prior aortic abdominal surgery (OR 1.98, CI 1.09-3.40, $p=0.04$), presentation with rupture & hypotension (OR 5.17, 2.18-12.30, $p < 0.001$), and thrombosis as surgical indication (OR 10.64, 3.76-30.07). No procedure specific variables were associated with LEI following AAA. LEI was associated with other adverse outcomes including increased length of stay (15.4 vs 8.2 days, $p=0.001$), increased ICU length of stay (6.6 vs 3.9 days, $p < 0.001$), other major complications (45.6% vs. 12.8%, $p < 0.001$), and death (23.5% vs. 5.5%, $p < 0.001$)

Abstract Body:

CONCLUSION: Lower extremity ischemia following abdominal aortic aneurysm repair, although rare, devours healthcare resources. Surgeons should be particularly vigilant for LEI when performing AAA repair with the use of iliac-branched devices and on patient's who have undergone prior abdominal surgery.

Presentation Number: P34

Publishing Title: Aortic Aneurysm Procedural Factors Implicated in Post-operative Renal Failure

Author Block: James C. Iannuzzi, MD, MPH, **Khurram Rasheed, MD**, Adam Doyle, John RT Monson, MB BCh, MD, Ankur Chandra, MD, Fergal J. Fleming, MB BCh, MD, Michael C. Stoner, MD
University of Rochester Medical Center, Rochester, NY

Background: As of yet small case-series were limited in their ability to estimate adjusted risk for renal failure following aortic surgery. This study hypothesized that new operative details would impact renal failure risk after both endovascular abdominal aortic aneurysm repair (EVAR), and open abdominal aortic aneurysm repair (OAR).

Methods: The Abdominal Aortic Repair procedure targeted NSQIP dataset for 2011-2012 was analyzed using bivariate analysis to identify factors associated with post-operative renal failure measured at 30-days. Factors meeting $p < 0.1$ were assessed for inclusion in a manual stepwise binary logistic multivariable model with the primary endpoint of post-operative renal failure. Variables that met final criteria of $p < 0.05$ were retained in final analysis.

Results: In total 2,785 EVAR and 949 OAR cases were included. Renal failure was identified in 1.9% ($n=52$) of EVAR and 9.2% ($n=87$) in OAR ($p < 0.001$). Significant procedure details on multivariable analysis within the EVAR group included iliac-branched devices (OR=2.32), and renal stenting (OR=2.73)(Table). Significant procedure details on multivariable analysis within the OAR group were presentation with hypotensive rupture (OR 39.72), supraceliac clamping (OR=2.21), and renal revascularization (OR=2.09)(table). On combined multivariable analysis OAR had an adjusted 3.69 times the risk for renal failure compared to EVAR.

Conclusion: This study for the first time reports a nationally representative adjusted risk for renal failure using procedure specific data. These data confirm the dismal renal prognosis in hypotensive patient's undergoing open repair of rupture aortic aneurysm, with a 40-fold risk for renal failure. The associated harm with adjunctive renal stenting in EVAR raises concern and demands attention given the increasing trend towards complex EVAR suggesting renal dysfunction may also become more prevalent with complex fenestrated approaches.

Abstract Body:

	Odds Ratio	Confidence Interval	P-Value
EVAR			
Preoperative Creatinine	1.50	1.23-1.83	<0.001
Preoperative Sepsis	3.15	1.36-7.30	0.007
ASA IV/V	2.19	1.14-4.21	0.019
Non-Elective	4.59	2.32-9.07	<0.001
Iliac-Branched Device	2.32	1.15-4.66	0.018
Renal Stent	2.73	1.16-6.41	0.022
OPEN			
Anemia	1.96	1.06-3.66	0.033
Obesity(BMI \geq 30)	2.46	1.46-4.15	0.001
Preoperative Creatinine	1.65	1.22-2.23	0.001
Presenting with Rupture and hypotension	39.72	2.53-624.70	0.009
ASA IV/V	2.13	1.19-3.82	0.011
Non-Elective	3.01	1.67-5.43	<0.001
Renal Revascularization	2.09	1.05-4.16	0.035
Supraceliac Clamp	2.21	1.23-3.97	0.008

**Presentation
Number:** P35

**Publishing
Title:** Optimizing SVC Occlusion Interventions: 2 Unusual Case Reports

Author Block: **Richard Schutzer, MD.**
Long Island Jewish, Lake Success, NY

OBJECTIVES: One of the most challenging patient populations in dialysis access are the ones with superior vena cava occlusion due to previous catheters and/or central venous interventions. Fortunately, patients can frequently collateralize adequately to prevent the need for intervention. Occasionally, such as in these 2 patients, collateralization is not enough.

METHODS: The first patient is a 33-year old female with renal failure attributed to mixed connective tissue disorder. She had multiple failed bilateral upper extremity access attempts along with 2 failed kidney transplants. She was currently receiving dialysis via a left brachial-axillary AVG, whose patency was maintained through the azygos system. She presented October 2013 with a catastrophic upper GI bleed. Her endoscopic findings were consistent with downhill esophageal varices.

The second patient is a 53-year old male with renal failure attributed to hypertension. He had bilateral lower extremity DVTs, multiple failed bilateral upper extremity access attempts, 2 failed kidney transplants, and 2 failed attempts at peritoneal dialysis. He was receiving dialysis via a left radial-cephalic AVF when there was a sudden deterioration in volume flows. On fistulogram, he was found to have acute thrombosis of his superior vena cava. Subsequent angiojet thrombectomy was complicated by chest pains and desaturation.

RESULTS: The first patient underwent an echocardiogram, followed by left axillary vein to atrial appendage bypass. She recovered well, with dramatic resolution of the varices on subsequent endoscopy. She is now 11 months out of surgery with a widely patent bypass.

The second patient underwent percutaneous recanalization of the right iliac vein to allow thrombectomy with angioplasty and stenting of the SVC under AngioVAC protection. He is now six months out of surgery being dialyzed through the fistula.

CONCLUSIONS: Intrathoracic pathology in dialysis access can be challenging even for the most seasoned vascular surgeon. Both percutaneous and open approaches have limited longevity and pose unique hazards. Based on this, the best approach is sometimes non-operative. In the included 2 patients, however, intervention was necessary. One was treated by an infrequently described atrial appendage. The other was treated by the first described use of AngioVAC in an AV fistula in the literature.

**Abstract
Body:**

Presentation Number: P36

Publishing Title: Multidisciplinary Approach to Transcatheter Aortic Valve Replacement (TAVR) access site planning: A Single Center Experience with Edwards SAPIEN™ Trans catheter Heart Valve (THV)

Author Block: Nicholas Sikalas, MD, Rajesh K. Malik, MD, Jason C. Kovacic, MD, Marvin V. Weaver, MD, Rami O. Tadros, MD, Ageliki G. Vouyouka, MD, Samin K. Sharma, MD, David H. Adams, MD, Michael L. Marin, MD, Peter L. Faries, MD, Sharif H. Ellozy, MD

The Mount Sinai Hospital, New York, NY

OBJECTIVE: At our institution a multidisciplinary team approach involving Cardiology, Cardiothoracic and Vascular surgery is used to plan appropriate access for Trans-catheter aortic valve delivery.

METHODS: 93 extremely high risk patients underwent placement of the Edwards SAPIEN™ Trans catheter Heart Valve (THV) for severe aortic stenosis over an 18 month period. CT Angiograms with 3-D reconstructions were reviewed for access vessel calcification, caliber, and tortuosity.

RESULTS: There were a total of 93 patients (67 females & 26 males) of which 46 underwent trans-femoral access (TF, 32 open, 14 percutaneous), 24 required iliac exposure (TI), 14 underwent trans apical (TA) approach and 9 direct-aortic (DA). TF was the default access if possible, followed by TI and then either TA or DA depending on surgical anatomy. Utilizing standardized access complication criteria (VARC-2) TF access offered the lowest complication rate. There were 0 major and 6(18.7%) minor vascular complications. TI exposure had major and minor complication rates of 7(29.1%) and 5(20.8%) respectively. Of the major complications 5 patients experienced hematomas requiring multiple transfusion, 2 required reoperation for suspected continued bleeding. The other 2 major complications include intra-op bleeding and an iliac artery dissection with thrombosis; all which were repaired successfully during the initial procedure. TA approach had 2(14.2%) major & 1(7.1%) minor complication. DA approach also resulted in 2(22.2%) major and 1(11.1%) minor vascular complication. Both TA and DA had 1 mortality each from ventricular perforation.

Abstract Body:

CONCLUSION: Appropriate access planning and selection is a major determinant in TAVR outcomes. Our success in our TAVR program is largely due to our Multidisciplinary approach to vascular access. TF is best when technically and anatomically feasible. When TF is limited by anatomic constraints, other approaches are acceptable.

Presentation Number: P37

Publishing Title: Perioperative and Survival Outcomes of Surgical Bypass Compared With Endovascular Therapy for Infrainguinal Peripheral Arterial Disease and Critical Limb Ischemia in the Vascular Quality Initiative

Author Block: Jeffrey J. Siracuse, MD, Denis Rybin, Jeffrey A. Kalish, MD, Mohammad Eslami, MD, Carla C. Moreira, MD, Robert T. Eberhardt, MD, Naomi M. Hamburg, MD, Alik Farber, MD
Boston University, Boston, MA

OBJECTIVES: There appears to be clinical equipoise in the management of patients with critical limb ischemia (CLI) and infrainguinal peripheral arterial disease (iPAD). We analyzed patient characteristics, perioperative complications, and long term mortality for lower extremity bypass (LEB) and percutaneous vascular interventions (PVI) for CLI within the VQI.

METHODS: VQI (2010-2013) was queried for patients with CLI and iPAD treated with LEB or PVI. We evaluated all patients (cohort 1) and those without comorbidities that would discourage bypass (severe CHF, ESRD, unstable angina, positive stress test, oxygen dependence, ASA class 4/5, previous major ipsilateral amputation, and urgent/emergent case) (cohort 2). Multivariate analyses were performed to analyze length of stay (LOS), perioperative mortality, and 3-year mortality.

RESULTS: There were 7897 patients in cohort 1 (4838 PVI and 3059 LEB) and 4579 (2452 PVI and 2127 LEB) in cohort 2. Patients treated with PVI had higher comorbidities across both cohorts (table, * = P<.05). Most common PVI complications included hematoma (3%), access site injury (0.2%) and readmission (2.4%); most common LEB complications included wound infection (3.3%), MI (3.2%), respiratory complications (2.7%). Median LOS for PVI was lower than LEB for both cohorts (1 vs. 4 days). After adjusting for comorbidities, patients treated with PVI had lower perioperative mortality in cohort 1 (2.1% vs. 2.4%) (OR 0.59, 95% CI 0.43-0.81, P<.01), but not cohort 2 (1.4% vs. 1.3%) (OR 0.66, 0.39-1.13, P=.13). Those treated with PVI had a higher mortality at three years in both cohort 1 (30% vs. 22%) (OR 1.2, 1.1-1.4, P<.01) and 2 (26% and 16%) (OR 1.6, 1.3-2.0, P<.01).

CONCLUSIONS: In VQI, PVI is more often offered to patients who are older and with more comorbidities. Patients offered LEB are more likely to have previous open and endovascular interventions. Patients treated with PVI had lower LOS in both cohorts and lower perioperative mortality in the full patient sample. There was no difference in perioperative mortality in lower risk patients. However, PVI had higher long-term mortality in both cohorts.

Abstract Body:

Patient characteristics				
Covariate	Cohort 1 PVI	Chort 1 LEB	Cohort 2 PVI	Cohort 2 LEB
Age	71*	68*	72*	68*
Diabetes	68%*	52%*	62%*	51%*
Smoking	63%*	81%*	63%	82%*
CHF	26%*	18%*	20%*	10%*
ESRD	17%*	8%*	-	-
Previous bypss	6%*	14%*	6%*	14%*
Previous PTA	15%*	21%*	16%*	22%*
Tissue Loss	76%*	62%*	74%*	59%*
Ambulatory	62%*	70%*	64%*	75%*

**Presentation
Number:** P38

**Publishing
Title:** Impact of “Do Not Resuscitate” Status on the Outcome of Major Vascular Surgery

Author Block: Jeffrey J. Siracuse, MD, Douglas W. Jones, MD, Ellen C. Meltzer, MD, Heather L. Gill, MD, Gregory G. Salzler, MD, Darren B. Schneider, MD, Peter H. Connolly, MD, Andrew J. Meltzer, MD.

New York-Presbyterian Hospital, Weill Cornell Medical College, New York, NY

OBJECTIVES: Patients with recent Do Not Resuscitate (DNR) orders may still be offered surgery to prolong life or improve its quality. The widely accepted approach of “required reconsideration” mandates that patients and surgeons discuss perioperative risks and expected outcomes in the context patient values and preferences. However, surgical outcomes in this patient population have not been well-defined. The objectives of this study are to assess outcomes in DNR patients undergoing major vascular procedures and develop an evidence basis for informed, shared decision making.

METHODS: Patients undergoing major vascular procedures were identified in the 2007-2010 National Surgical Quality Improvement Project (NSQIP). DNR Patients were defined as those with an active DNR order within 30 days prior to surgery. Demographics, co-morbidities, procedural details, and complications were compared to those without DNR orders. To isolate the impact of DNR status, multivariate regression and 1:1 propensity score matching were used to compare outcomes between DNR patients and a non-DNR cohort of comparably high risk patients.

RESULTS: Of 108,714 patients undergoing major vascular surgery, 1565 (1.4%) had active DNR orders 30 days preceding surgery. DNR patients were more likely to be functionally dependent (69% vs. 15%; $P < .001$), >80 years old (53% vs. 20%; $P < .001$), and suffer from a variety of cardiac, pulmonary, and systemic comorbidities. The most common procedures in DNR patients were major amputation (38.4%), lower extremity bypass (20%), and peripheral thromboembolectomy (11.7%). Unadjusted 30-day mortality was significantly higher among DNR patients (21% vs. 3.4%; $P < .001$). After 1:1 propensity score matching, 2 cohorts of 1538 patients differed only with respect to DNR status. Mortality remained significantly higher among DNR patients (21% vs. 13%; $P < .001$). There was a trend towards reduced CPR in DNR patients (1.7% vs. 2.6%; $P = 0.07$).

CONCLUSION: Patients with recent DNR status are at high risk for major complications and mortality after vascular surgery. Compared to a matched cohort of “high risk” non-DNR patients, those with recent DNR orders suffered equivalent rates of post-operative morbidity, but markedly increased mortality. This suggests that DNR status, independent of co-morbidities and perioperative complications, increases the risk of “failure to rescue” and mortality. This has implications not only for risk adjustment, but also provides an evidence basis for shared decision making in challenging circumstances.

Presentation Number: P39

Publishing Title: Hybrid Technique for Excluding Large Femoral Anastomotic Pseudoaneurysms After Aortobifemoral Bypass

Author Block: Ashley Tameron, MD, Sophia Afridi, MD, Nessa Miller, MD, Patrick Muck, MD, Matthew Recht, MD.
Good Samaritan Hospital, Cincinnati, OH

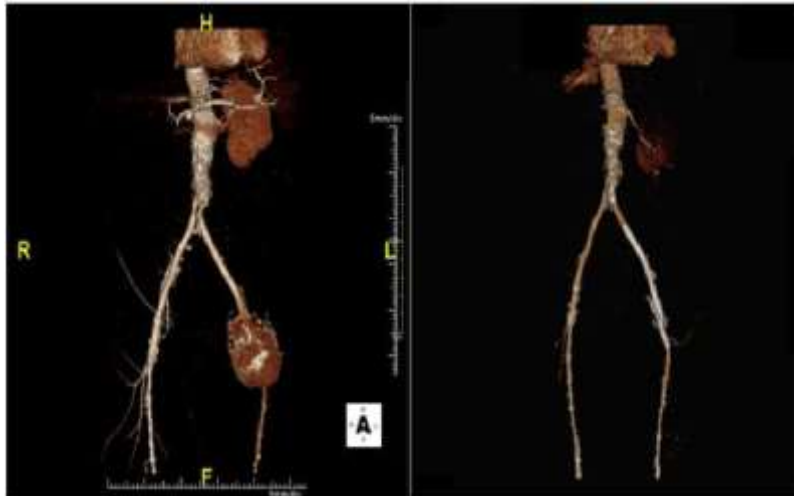OBJECTIVE: Arterial pseudoaneurysms are known complications after endovascular procedures and open vascular surgeries. The femoral region is the most common site for anastomotic pseudoaneurysms. Significant morbidity and mortality are associated with conventional open pseudoaneurysm repairs. Since Dr. Parodi's report in 1991, endovascular techniques have proven successful in aneurysm repair to decrease postoperative morbidity and long term mortality. Our goal is to detail a novel use of hybrid endovascular exclusion technique in femoral anastomotic pseudoaneurysms.

METHODS: The superficial femoral artery and profunda femoral artery were exposed through an undissected plane distal to the previous operative site under general anesthesia. A 9 French sheath was placed into superficial femoral artery in retrograde fashion. Retrograde arteriograms were performed identifying the native external iliac and profunda femoral arteries. The external iliac artery was embolized, as it was patent in both patients. Sequential, overlapping (9 mm, 8 mm, 7 mm) ViaBahn® stent grafts were inserted from the aortobifemoral limb into the SFA. Once completion arteriogram showed exclusion of the pseudoaneurysm, the profunda femoral was translocated onto the SFA distal to ViaBahn® graft via an open incision.

RESULTS: This technique was successfully used in two patients who had a remote history of aortobifemoral bypasses and distal anastomotic pseudoaneurysms. The first case was a 78 year old man with multiple medical comorbidities including a newly diagnosed lung cancer and a left lower quadrant end colostomy. His symptomatic 10 cm left femoral anastomotic pseudoaneurysm was repaired successfully using this hybrid technique. The second case was a 79 year old woman with significant cardiopulmonary comorbidities. Her 14 cm right femoral anastomotic pseudoaneurysm was successfully treated with this hybrid technique. At latest follow up, both patients had patent repairs.

CONCLUSIONS: The gold standard of femoral anastomotic pseudoaneurysm treatment, open surgical repair, may not be possible in patients with multiple medical comorbidities or specific anatomic factors. The described hybrid technique allows safe and effective repair of large femoral anastomotic pseudoaneurysms.

Abstract Body:



Presentation Number: P40

Publishing Title: Post-TEVAR Recurrent Type IB Endoleak: Treatment with Extension Cuffs and Endovascular Debranching

Author Block: Nikita Tihonov, MD, Chad Jacobs, MD, Bulent Arslan, MD, Gerard DeCastro, MD, Walter McCarthy, MD.
Rush University Medical Center, Chicago, IL

OBJECTIVE: The case involves redo-TEVAR with endovascular debranching of the celiac and SMA utilizing snorkel technique in a 72yo female with ESRD and recurrent type IB endoleak leading to enlargement of the aneurysmal component of the visceral segment aorta. Patient underwent TEVAR with Medtronic Talent stent graft in 2008 for treatment of a 6cm thoracic aortic aneurysm secondary to chronic type B aortic dissection. Endovascular cuff extensions and coil embolization were required for management of a type IB endoleak, which developed one year postoperatively. A recent CTA of the chest revealed a recurrent type IB endoleak with the increased diameter of the aneurysmal sac to 8cm. (Fig.1a,b).

METHODS: Redo-TEVAR and endovascular debranching was performed via bilateral femoral artery percutaneous access and a left axillary artery cutdown. The celiac and SMA arteries were preserved utilizing Viabahn and iCAST stents via snorkel technique from the left axillary artery access. A Medtronic Valiant Captivia endograft was deployed to cover the type IB endoleak and to bridge the previously placed Talent endograft. This was positioned 5mm below the uppermost edge of the visceral stents to maintain visceral perfusion.

Abstract Body:

RESULTS: Completion arteriogram demonstrated successful placement of the Valiant endograft with excellent brisk flow into both the celiac and SMA. There was no evidence of the type I endoleak. (Fig.1c). CTA two weeks post-procedure confirmed the absence of the type I endoleak and decreased size of the aneurysmal sac to 6.8cm.(Fig.1d).

CONCLUSION: Endoleak is a complication of endovascular management of AAA and TAA. Involvement of the endoleak at critical aortic branches, such as the visceral segment, can be particularly challenging. Hybrid treatment with distal aortic extension cuffs and open surgical visceral debranching has been described. This report illustrates an endovascular approach to redo-TEVAR using distal aortic endograft extensions with endovascular debranching via snorkel technique. This approach, using percutaneous femoral access for the extension cuffs and an axillary cutdown for the visceral snorkels, is a viable alternative in treating difficult endoleaks at critical aortic branches in selected cases.

Fig.1(a-d).

Presentation Number: P41

Publishing Title: Providing Vascular Surgical Care for Lower Extremity Ischemia from a Socioeconomic Perspective

Author Block: Daniel J. Torrent, MD¹, Michael C. Stoner, MD², Frank M. Parker, MD¹, William M. Bogey, MD¹, C. Steven Powell, MD¹, David W. Barham¹, Nishika S. Patel¹, Avery G. Colomb¹, Dean J. Yamaguchi, MD¹
¹East Carolina University, Greenville, NC, ²University of Rochester, Rochester, NY

OBJECTIVES: Socioeconomic status as it influences vascular patient care has not been studied. The purpose of this study is to evaluate the impact of socioeconomic status on patients with lower limb ischemia in eastern North Carolina.

METHODS: All referrals through clinic and hospital transfer over an eight month period from 2013 through 2014 were recorded. Patient demographics, diagnosis, comorbidities, payer source, county of residence, and date of transfer were also recorded. Age and comorbidities were used to calculate Charlson Comorbidity Index (CCI). Census data described the median income per capita for each county. Univariate statistics were used for the associations between day of week of transfer and payer source. For patients transferred with lower extremity ischemia, the percentage transferred with critical limb ischemia was calculated.

Univariate and multivariate statistics describing the association between mean per capita income and county of residence as well as race were calculated.

Abstract Body:

RESULTS: There were a total of 1299 patients with the majority of transfers taking place on Monday (312), Tuesday (234), Wednesday (335), and Thursday (301). There were a total of 440 patients transferred for lower extremity ischemia with 30.7% having critical limb ischemia. Factors associated with presenting with critical limb ischemia were having a federal payer source ($P = 0.04$) compared to a private payer, being from a county with a median income per capita before the median for the region ($P = 0.02$), and per capita income of the county as a linear variable ($P = 0.05$), being non-Caucasian ($P = 0.01$), age ($P = 0.02$), CCI ($P = 0.01$). By logistic regression, a federal payer source increased the odds of presenting with CLI by 2.3 times (95% CI 1.11-5.28) when controlling for race ($P = 0.002$), age ($P = 0.03$), and relation to the median county of residence income ($P = 0.14$).

CONCLUSIONS: Lower income patients residing in eastern North Carolina who rely upon federally funded insurance trend towards seeking vascular care at a later stage of disease (i.e. critical limb ischemia). This is probably a result of economic strain as well as limited resources and education.

Presentation Number: P42

Publishing Title: Symptomatic High Flow Arteriovenous Fistula of the Lower Extremity in an Adult With No History of Trauma

Author Block: Eric Trestman, MD, John Phair, MD, Ratna Medicherla, MD, Jennifer Stableford, MD
Montefiore Medical Center, Bronx, NY

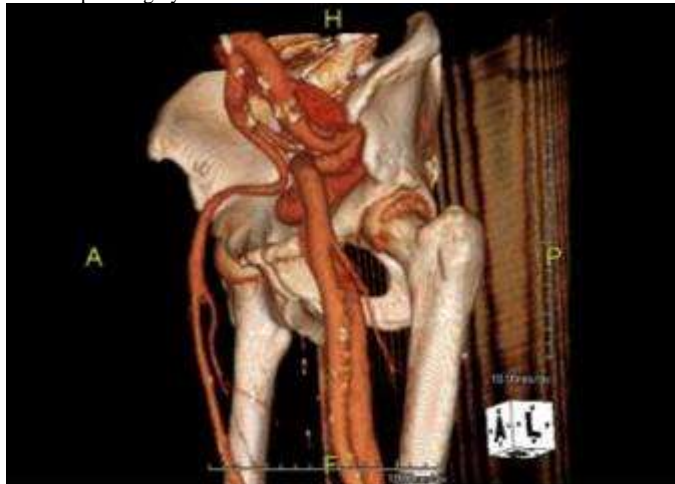
OBJECTIVES: To report a symptomatic high output arteriovenous fistula of the left lower extremity with no history of trauma successfully treated conservatively with compression therapy.

METHODS: An extensive literature search was performed using the MEDLINE and Pubmed databases with substantial results in existing literature in regards to symptomatic lower extremity arteriovenous fistulae resulting in high output heart failure. However, the vast majority of these cases are linked to trauma. There are no cases in the current literature describing a massive, likely primary arteriovenous fistula remaining asymptomatic until adulthood.

RESULTS: Case Report: We report a case of a left common femoral artery common femoral vein arteriovenous fistula found while the patient was undergoing workup of new onset heart failure. High flow arteriovenous fistula of the lower extremity, particularly cases which involve the patient becoming symptomatic in adulthood are the result of trauma. This is the only case in the current literature of primary arteriovenous fistulae resulting in high output heart failure as an adult. Furthermore, as this patient was a poor operative candidate due to extensive co morbidities and the lesion was not amenable to endovascular repair, we attempted the novel approach of using conservative compression therapy in this setting which yielded substantial relief of the patients symptoms of high outflow heart failure and lower extremity swelling.

CONCLUSIONS: This case represents the rare entity of a primary high flow arteriovenous fistula which became symptomatic well into adulthood. High output heart failure is a well-documented and described sequelae of post-traumatic arteriovenous fistulae. This case may represent a number of undiagnosed arteriovenous malformation which remain largely asymptomatic. Furthermore, this case illuminates an alternative to invasive treatment of these complex lesions in patients who may not be able to tolerate open surgery and whose lesions are not amenable to endovascular intervention.

Abstract Body:



Presentation Number: P43

Publishing Title: Endovascular Repair of a Thoracoabdominal Aortic Aneurysm associated with Q Fever (*Coxiella burnettii*)

Author Block: Andrew Unzeitig, MD, Jonathan Imran, MD, Mark Swancutt, MD, Rawson James Valentine, MD, Carlos Timaran, MD. UT Southwestern, Dallas, TX

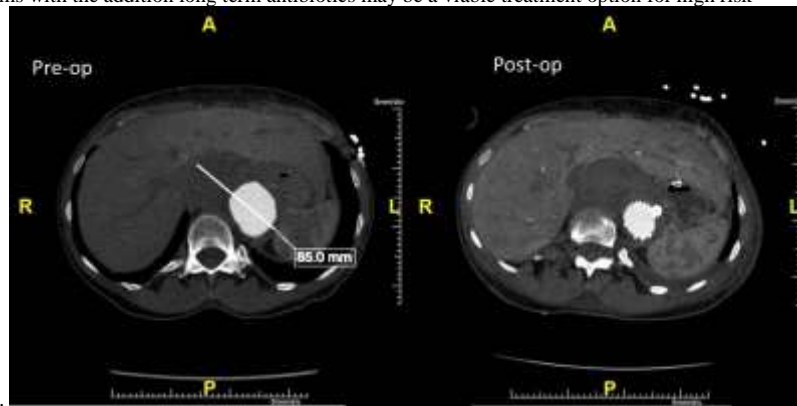
OBJECTIVES: Q fever is caused by the bacterium *Coxiella burnettii*, an intracellular pathogen. Chronic infections are frequently associated with cardiovascular complications, usually endocarditis, but are also linked to aortic aneurysms and vascular graft infections. Rapid treatment of infection as well as surgical management of infections has been associated with improved outcomes. There has been a few reports of Q fever associated thoracoabdominal aneurysm including one treated with open repair using rifampin soaked polyester graft. Endovascular treatment of a thoracoabdominal aneurysm associated with Q fever has not been described.

METHODS: We present a case of a high risk patient that presented with a symptomatic 8.5 cm thoracoabdominal aneurysm, Crawford type III, caused by Q fever. Initially this patient had a small thoracoabdominal aneurysm discovered during a cardiac catheterization performed for acute myocardial infarction. She presented 18 months later with rapid enlargement of the aneurysm, abdominal pain and dysphagia. She had a several week history of weakness and fatigue but no fevers. Serologies were positive for chronic Q fever infection. Treatment consisted initially of antibiotic therapy begun preoperatively and continued postoperatively. The patient underwent endovascular repair using a surgeon-modified polyester stent-graft that was soaked in rifampin.

RESULTS: The patient recovered from her procedure and was discharged post-operative day 9. A CT scan obtained 30 days post-operatively showed complete exclusion of the aneurysm with no endoleak, she remains pain free. She is to continue a prolonged course of oral antibiotics.

CONCLUSIONS: The incidence of aneurysms related to Q fever is probably under-recognized. The diagnosis should be considered in cases of suspected mycotic aneurysms with negative cultures. Endovascular treatment of thoracoabdominal aneurysms with the addition long term antibiotics may be a viable treatment option for high risk

Abstract Body:



patients.

**Presentation
Number:** P44

**Publishing
Title:** Endovascular Repair of Multi-Vessel Type II Endoleak with Single Site Brachial Artery Access

Author Block: Biren K. Juthani, DO, Ian Schlieder, DO, Richard Hsu, MD, PhD.
Danbury Hospital, Danbury, CT

**Abstract
Body:**

OBJECTIVES: Endovascular repair of aortic aneurysms is associated with decreased perioperative morbidity compared to open aneurysm repair. Between 10-25% of EVARs are complicated by an endoleak. Type II endoleak is defined as retrograde flow of blood into the aneurysm sac by aortic branch vessels. We describe a case report of a type II endoleak, with repair indicated by sac expansion, involving embolization of five arteries providing flow into the aneurysm sac, performed through a single site brachial artery percutaneous access.

METHODS: A 74 year old man with a 5.8 cm infrarenal AAA had undergone an EVAR two years prior. Surveillance imaging demonstrated type II endoleak from the accessory right renal artery (aRRA), inferior mesenteric artery (IMA), L3 & L4 lumbar arteries (L3A, L4A) and middle sacral artery (MSA). Using brachial access, we catheterized the superior mesenteric artery, entered the meandering mesenteric artery and thus the aneurysm sac via the IMA (Figure 1). Angiogram confirmed sac entry with subsequent embolization of the aRRA, sac cavity and IMA with Nester platinum 0.018 inch coils. We then accessed and embolized the MSA via the ascending lumbar branch off the posterior division of the left internal iliac artery. Next L3A and L4A were individually accessed and coil embolization was also performed.

RESULTS: Completion angiogram showed cessation of flow into the aneurysm sac. Follow up imaging at postoperative month 1 and 5, respectively, revealed resolution of the type II endoleak with gradual aneurysmal sac shrinkage.

CONCLUSIONS: The management of Type II endoleaks remains controversial with aneurysmal dilatation being the primary marker for intervention. Options for repair include: conversion to open surgery, suture ligation of the feeding arteries (with the aneurysm open or intact), laparoscopic ligation or clipping of the feeding arteries, coil embolization of the feeding arteries, coil embolization of the endoleak cavity, and polymer embolization of the endoleak cavity. The transcatheter therapies can be accomplished through transarterial (usually transfemoral) or through translumbar access. Our case demonstrates that through a single site brachial arterial access, it is possible to embolize multiple arterial branches feeding the aneurysm sac. This potentially decreases the risk of access site complications.

Presentation Number: P45

Publishing Title: Spontaneous Healing of an Acute Complicated Type B Aortic Dissection with Medical Therapy

Author Block: Naved U. Saqib, MD, Faryan Jalalabadi, BS, Kristofer Charlton-Ouw, MD, Anthony L. Estrera, MD, Hazim J. Safi, MD, Ali F. Azizzadeh, MD.

University of Texas Health Sciences Center at Houston, Houston, TX

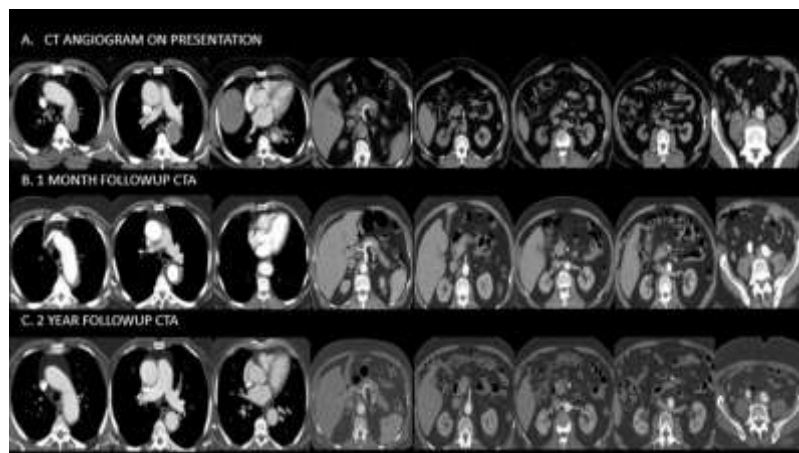
OBJECTIVES: Spontaneous healing (thrombosis and complete obliteration of the false lumen) in patients with acute complicated Type B aortic dissection (ACTBAD) is extremely rare. ACTBAD often requires endovascular or open surgical intervention. Thoracic endovascular aortic repair (TEVAR) has rapidly replaced open surgery as the less invasive option. We report a case of a spontaneous healing of ACTBAD in a patient who underwent an unsuccessful attempt at endovascular repair.

METHODS: A 71-year-old man with hypertension and morbid obesity presented with acute back pain and lower extremity numbness. Computed tomographic angiography (CTA) revealed an acute type B aortic dissection with severe compression of the true lumen (Figure 1.A). Aggressive anti-impulse medical therapy was initiated. The patient developed worsening abdominal pain and acute renal failure despite medical therapy. He was taken to the operating room for intravascular ultrasound (IVUS) and intent to treat with TEVAR. Intraoperative IVUS revealed a thrombosed and severely compressed true lumen. Limited flow from the false lumen was visualized in celiac, superior mesenteric and renal arteries. TEVAR was aborted due to inability to cross the true lumen into the ascending thoracic aorta. Aggressive medical therapy was continued. He was discharged to a long term facility on hospital day 7. A follow up visit was scheduled in 4 weeks, 6 months and yearly thereafter.

RESULTS: At the time of the follow-up visit, the patient was making satisfactory recovery. The 1 month follow-up CTA demonstrated spontaneous healing of the dissection, patent celiac, superior mesenteric, renal and iliac arteries, and no dissection flap was visualized (Figure 1.B). The 6 month, 1 year and 2 year follow-up CTA (Figure 1.C) demonstrated complete healing of the ACTBAD without aneurysmal degeneration.

CONCLUSIONS: We report spontaneous healing and resolution of ACTBAD while on medical therapy, followed clinically and with serial imaging for 2 years. To our knowledge, this represents the first spontaneous healing of an ACTBAD reported in the literature.

Abstract Body:



**Presentation
Number:** P47

**Publishing
Title:** Endovascular Treatment of Recurrent Aortic Coarctation

Author Block: Allan W. Tulloch, MD, William Quinones-Baldrich, MD
UCLA, Los Angeles, CA

**Abstract
Body:**

OBJECTIVES: Patients with aortic coarctation diagnosed at a young age often undergo surgical repair. Recurrence of aortic coarctation in adults presents with exercise intolerance, hypertension, and or claudication. We present our experience with the use of endovascular techniques for the treatment of recurrent aortic coarctation.

METHODS: Three patients with recurrent aortic coarctation after surgical repair presented with hypertension (2), claudication (1) and aneurysm formation (1). The original repair had been performed 8 to 16 years prior to presentation. In one patient the initial recurrence was treated with a left ventricle to descending thoracic aortic bypass which failed four years later.

RESULTS: The recurrent coarctation was treated in two patients with a combined endovascular and surgical repair. Both patients required a Palmaz stent within the endograft at the stenotic segment in addition to the endovascular graft. In both patients, there was resolution of the pressure gradient. Temporary hypotension by the administration of adenosine or rapid ventricular pacing was used in both cases during deployment of the Palmaz stents. The third patient had endovascular repair of an aneurysm with an endovascular graft across the previous repair. There was no mortality. All patients remain asymptomatic on follow-up (16 months to 48 months).

CONCLUSIONS: Recurrent stenosis after aortic coarctation repair can be a challenging problem. Endovascular technology can be applied to the treatment of recurrent aortic coarctation reducing the risk of re-intervention. Resolution of a pressure gradient may require additional radial force using a balloon expandable stent.